

Bilateral Massive Ovarian Luteinized Follicular Cysts of a Twin Pregnancy

Li-Song Teng^{1*}, Ke-Tao Jin^{1,2}, Kui-Feng He¹, Tie-Ming Zhu², Fan Zhao³, Zhi-Gang Jin²

¹Department of Surgical Oncology, The First Affiliated Hospital, School of Medicine, Zhejiang University, Hangzhou, ²Department of Surgery, Zhuji Hospital, Zhuji, and ³Department of Gynecology and Obstetrics, Red Cross Hospital of Zhuji, Zhejiang, China.

We report a case of rare bilateral massive ovarian luteinized follicular cysts in a twin pregnancy. A 28-year-old, gravida 1, para 0, abortus 0 woman was incidentally found to have bilateral massive ovarian cysts (left side, 12 × 10 × 8 cm; right side, 15 × 10 × 6 cm) during the cesarean delivery of a twin pregnancy at 36 weeks of gestation. After 1,950-g and 2,350-g female babies were delivered in good condition, the patient received bilateral oophorectomy. Subsequent histopathology led to the diagnosis of giant bilateral ovarian luteinized follicular cysts. [*J Chin Med Assoc* 2010;73(12):644–646]

Key Words: ovarian luteinized follicular cysts, pathogenesis, twin pregnancy

Introduction

Ovarian luteinized follicular cyst is a relatively uncommon benign condition characterized by bilateral or solitary ovarian enlargement during pregnancy and is secondary to high maternal human chorionic gonadotropin (HCG) serum levels, which occur under several conditions.¹ Twin pregnancy associated with bilateral massive ovarian luteinized follicular cysts is even more uncommon.

Regular prenatal check-up is routine and highly recommended for every pregnant woman, since it is important for improving women's health. With routine obstetric ultrasound examinations, ovarian cysts are now more commonly diagnosed during pregnancy, and their management is still a challenging clinical issue among obstetricians. Ovarian luteinized follicular cyst, a cause of ovarian enlargement during pregnancy, is a self-limiting disease that can regress spontaneously after labor. The complications of the disease include ovarian torsion, intracystic hemorrhage, and rupture.^{2–5}

We report here the case of a 28-year-old woman with bilateral massive luteinized follicular cysts that were incidentally discovered during cesarean delivery of a twin pregnancy at 36 weeks of gestation. A lower

uterine segment cesarean section and resection of bilateral ovarian cysts were performed on the patient.

Case Report

A 28-year-old, gravida 1, para 0, abortus 0 woman, with a normal menstrual history, was initially seen at 36 weeks of gestation with a twin intrauterine pregnancy. She was admitted to the hospital because of premature rupture of the membranes associated with vaginal discharge. Physical examination revealed that her heart rate was 88 beats/min, respiration rate was 24 breaths/min, blood pressure was 110/70 mmHg, and temperature was 37.0°C. The patient's abdomen was distended. Bowel sounds were present but infrequent. The uterus was enlarged to no more than 36 weeks' gestational size.

First, a lower segment cesarean section was performed. During the operation, approximately 150 mL of ascites overflowed from the verge of the incision when the peritoneum was opened. We explored the abdominal cavity and found a giant left ovarian cyst (12 × 10 × 8 cm) and a partially ruptured giant right ovarian cyst (15 × 10 × 6 cm). The left ovary was



*Correspondence to: Dr Li-Song Teng, Department of Surgical Oncology, The First Affiliated Hospital, School of Medicine, Zhejiang University, 79, Qingchun Road, Hangzhou, Zhejiang 310003, China.
E-mail: lsteng@hos.zju.edu.cn • Received: January 20, 2010 • Accepted: May 27, 2010

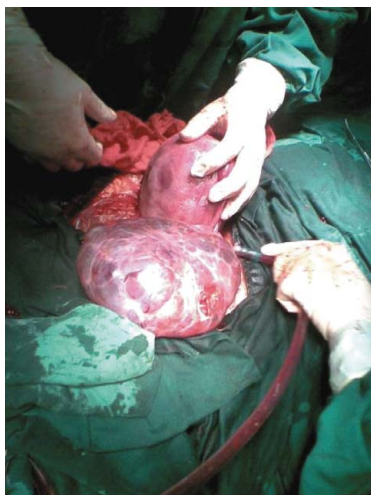

Figure 1. Gross appearance of the left ovary during the operation. An enlarged $12 \times 10 \times 8$ cm ovarian cyst was observed. The left ovary was smooth-walled, multiloculated and without solid elements, and replaced by multiple cysts of varying size. The right ovary had already been partially ruptured and it was completely ruptured during the operation.

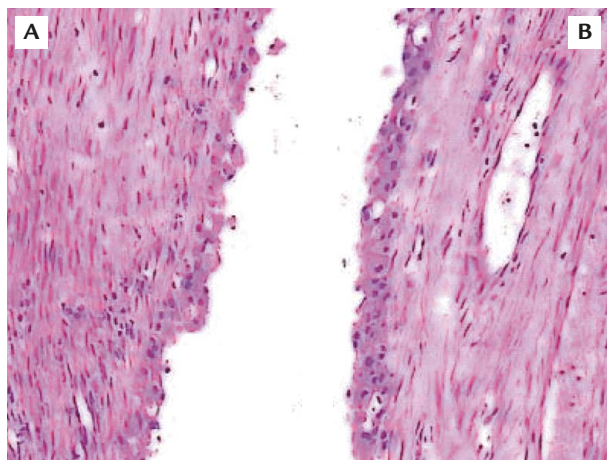


Figure 2. Histological sections show ovarian luteinized follicular cysts. Microscopic examination revealed that they were lined by luteinized cells that exhibited focal marked nuclear anomaly (hematoxylin & eosin, $200\times$): (A) tissue from the left ovary; (B) tissue from the right ovary.

smooth-walled, multiloculated and without solid elements, and was replaced by multiple cysts of varying size (Figure 1). The right ovary was already partially ruptured and completely ruptured during the operation. We considered that they were benign cysts. After 2 female infants (1,950 g, 48 cm and 2,150 g, 50 cm) were delivered in good condition, the patient received bilateral oophorectomy.

Subsequent histopathology led to the diagnosis of giant bilateral ovarian luteinized follicular cysts (Figure 2), as microscopic examination showed that they were lined by luteinized cells that exhibited focal

marked nuclear anomaly. The patient's postoperative course was unremarkable.

Discussion

To date, only 1 case of giant bilateral ovarian luteinized follicular cysts associated with normal pregnancy³ and 12 cases of giant solitary ovarian luteinized follicular cyst of pregnancy and puerperium have been reported.^{2,4-7} These cysts were found during pregnancy or puerperium, or with a unilateral ovarian cyst during cesarean delivery at term, and they had a median diameter of 25 cm. There are no other cases of bilateral massive ovarian luteinized follicular cysts of twin pregnancy in Chinese women reported in the English literature. In our case, the patient presented with bilateral massive ovarian cysts during cesarean delivery at term. There was no recognized association with endocrine abnormalities. It is unclear what the stimulus is for abnormal follicle growth; it has been postulated that there is an abnormality in the pituitary release of gonadotropins or in the stimulus to the ovary from HCG.^{8,9} Le Vaillant et al¹⁰ showed that ovarian luteinized follicular cyst is related to hyperreactio luteinalis (HRL), which is rarely observed in normal pregnancy. Its clinical spectrum consists of benign development of often bilateral luteinized cysts and it may be revealed by an overproduction of androgens. HRL is usually associated with an excessive production of HCG in either trophoblastic disease or hyperplacentalosis (Rh-alloimmunization or diabetes), but in 60% of cases, HRL may occur in normal pregnancies. The pathophysiology of HRL in pregnancy involves an increased sensitivity of ovarian stromal cells to HCG.¹⁰

Ovarian luteinized follicular cysts should be compared with luteoma. Luteoma is more frequent with multipara, whereas ovarian luteinized follicular cysts are more often seen with unipara. Ovarian luteinized follicular cysts and luteoma are usually found by chance. The pathology must be known because of their spontaneous regression after delivery.¹¹

Pregnancy associated with significant bilateral massive ovarian luteinized follicular cysts may require surgical intervention when abnormal masses are palpated with or without localizing signs. Ovarian cysts can be diagnosed during pregnancy with routine obstetric ultrasound examinations. In our case, the patient was a handicraftswoman from a remote mountain area who settled in a community near our hospital approximately 1 month before admission. She had not, therefore, received routine obstetric ultrasound examinations. When she arrived at our department, because of premature

rupture of the membranes associated with vaginal discharge, she immediately required cesarean delivery. It is possible that, because of the emergency nature of the situation, our sonographer concentrated on the ultrasonic examination only and failed to recognize the potential pathological changes in the adnexa uteri. Based on the findings from our case, it is suggested that ultrasound examination alone should not be used to determine obstetric changes during pregnancy. A careful examination of the adnexa uteri is also required.

It is controversial to perform bilateral oophorectomy in young women. A frozen section diagnosis of the ovary before oophorectomy is a reasonable approach as it can help determine whether or not resection should be performed. Ovarian function, even in young women who have completed childbearing, should be preserved as much as possible when bilateral ovarian cysts occur. In our case, management of the patient could be seen as being too aggressive, as it could have resulted in serious consequences, such as the patient not being able to have more children at a young age. However, during the operation, we found that the right ovary was completely ruptured, and there were no preservable ovarian tissues with a normal structure in either ovary. Bilateral oophorectomy was performed, therefore, after an informed consent form was signed by her husband.

The identification of benign or malignant giant cysts with medical imaging before surgery is valuable for clinical application. In our case, there were 3 reasons why the patient did not have regular and differential diagnosis. First, it was an emergency case. Second, there were no imaging results for reference when the woman arrived at our department. Third, the patient presented with bilateral massive ovarian cysts during cesarean delivery at term.

Acknowledgments

This project was supported by the State Key Basic Research and Development Program of China (973 Program, grant no. 2009CB521704) and the National High-tech Research & Development Program of China (863 Program, grant no. 2006AA02A245).

References

1. Saltzman M, Drut M, Drut R. Luteinized cystic ovarian hyperplasia associated with placentomegaly due to chorangiomas. *Fetal Pediatr Pathol* 2005;24:31-7.
2. Clement PB, Scully RE. Large solitary luteinized follicle cyst of pregnancy and puerperium: a clinicopathological analysis of eight cases. *Am J Surg Pathol* 1980;4:431-8.
3. Laohapand T, Suwanprakorn P, Budthimedhee V, Stitnimankarn T. Bilateral multiple luteinized follicular cysts associated with normal pregnancy: a case report. *J Med Assoc Thai* 1981;64:312-4.
4. Roth LM, Ehrlich CE, Ellis GH. Large luteinized follicular cyst of pregnancy and puerperium. *South Med J* 1988;81:805-6.
5. Thomas S, Krishnaswami H, Seshadri L. Large solitary luteinized follicle cyst of pregnancy and puerperium. *Acta Obstet Gynecol Scand* 1993;72:678-9.
6. Albukerk JN, Berlin M. Unilateral lutein cyst in pregnancy. *N Y State J Med* 1976;76:259-61.
7. Kott MM, Schmidt WA. Massive postpartum corpus luteum cyst: a case report. *Hum Pathol* 1981;12:468-70.
8. Caspi E, Schreyer P, Bukovsky J. Ovarian lutein cysts in pregnancy. *Obstet Gynecol* 1973;42:388-98.
9. Danon M, Robboy SJ, Kim S, Scully R, Crawford JD. Cushing syndrome, sexual precocity, and polyostotic fibrous dysplasia (Albright syndrome) in infancy. *J Pediatr* 1975;87:917-21.
10. Le Vaillant C, Tremouilhac C, Boog G. Luteinized cystic ovarian hyperplasia during a normal pregnancy. *J Gynecol Obstet Biol Reprod (Paris)* 2003;32:368-74. [In French]
11. Degrolard M, Douvier S, Feldman JP, Henriques E, Mavel A. Luteinized cystic hyperplasia of the ovaries during pregnancy: a case report. *J Gynecol Obstet Biol Reprod (Paris)* 1992;21:569-72. [In French]