

An Uncommon Cause of Hiccups: Sarcoidosis Presenting Solely as Hiccups

Lien-Fu Lin*, Pi-Teh Huang

Division of Gastroenterology, Department of Internal Medicine, Tung's Taichung Metrobarbor Hospital, Taichung, Taiwan, R.O.C.

Common causes of hiccups are over-distension of the stomach, a sudden change in gastrointestinal temperature, excessive alcohol and tobacco ingestion, and sudden excitement or emotional changes. Common presenting symptoms of sarcoidosis include cough, dyspnea, and chest pain. It is very rare for a sarcoidosis patient to present with hiccups. A 48-year-old man presented with hiccups of 2 weeks' duration. He denied having headaches, earache, cough, abdominal pain, fever, or body weight loss history. On physical examination, he had no peripheral lymphadenopathies in the neck, axilla and inguinal regions, no organomegaly in the abdomen and no skin abnormalities. A neurological examination showed normal findings. Laboratory investigations revealed a normal complete blood count, liver function, renal function, serum calcium, and tumor markers. Transabdominal ultrasound was negative, and panendoscopy revealed a small healing duodenal ulcer. Chest radiography showed an enlarged right lung hilum, while computed tomography showed enlargement of multiple mediastinal lymph nodes. Endoscopic ultrasound-guided fine-needle aspiration with a 22-gauge needle and trucut biopsy with a 19-gauge needle (quick-core biopsy needle) were performed, and cytology, cell block and histology revealed non-caseating granuloma, with negative tuberculous and fungus cultures. Mediastinal lymph node due to sarcoidosis can be a rare cause of hiccups. [*J Chin Med Assoc* 2010;73(12):647–650]

Key Words: endoscopic ultrasound-guided fine-needle aspiration, hiccups, mediastinal lymph node, sarcoidosis

Introduction

A hiccup is an involuntary contraction of the diaphragm and intercostal muscles, causing sudden inspiration and abrupt closure of the glottis. The reflex arc of a hiccup is composed of an afferent limb, including the vagus and phrenic nerves, sympathetic chain, a central mediator, and an efferent limb, including the phrenic nerve, with accessory efferent neural connections to the glottis and inspiratory intercostal muscles.¹ Common causes of hiccups are over-distension of the stomach, a sudden change in gastrointestinal temperature, excessive alcohol and tobacco ingestion, and sudden excitement or emotional changes.² We present a case of sarcoidosis who presented solely with hiccups.

Case Report

A 48-year-old man presented with hiccups of 2 weeks' duration. He denied having headaches, earache, cough,

abdominal pain, fever, or body weight loss. On physical examination, he had no peripheral lymphadenopathies in the neck, axilla and inguinal regions, no organomegaly in the abdomen, and no skin abnormalities. Neurological examination results were normal.

Laboratory investigations revealed a normal complete blood count, liver function, renal function, serum calcium, globulin and tumor markers. Transabdominal ultrasound was negative, and panendoscopy showed a small healing duodenal ulcer. Chest radiography revealed an enlarged right lung hilum (Figure 1), while computed tomography showed multiple mediastinal lymph node enlargement (Figure 2). Endoscopic ultrasound-guided fine-needle aspiration (EUS-FNA) with a 22-gauge needle (Echotip; Cook Endoscopy, Winston-Salem, NC, USA), and trucut biopsy (quick-core biopsy needle; Cook Endoscopy) were performed (Figure 3). Cytology, cell block and histology (Figure 4) showed non-caseating granuloma, with no acid-fast bacilli, and cultures for *Mycobacterium tuberculosis* and fungus were negative. Polymerase chain reaction



*Correspondence to: Dr Lien-Fu Lin, 8, 11th Floor, Mei Tsun Road, Section 2, Lane 168, Taichung 402, Taiwan, R.O.C.

E-mail: aucardla@yahoo.com.tw • Received: November 30, 2009 • Accepted: May 7, 2010

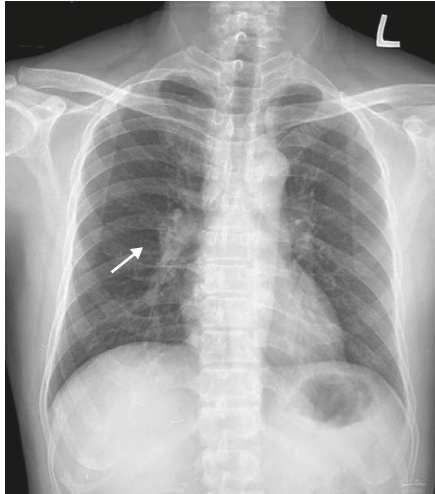


Figure 1. Enlarged right hilar region (arrow).

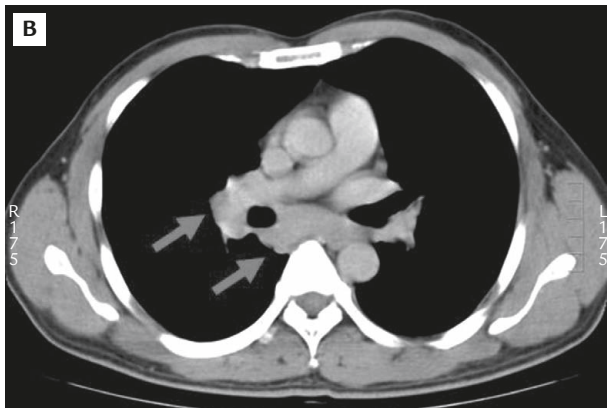
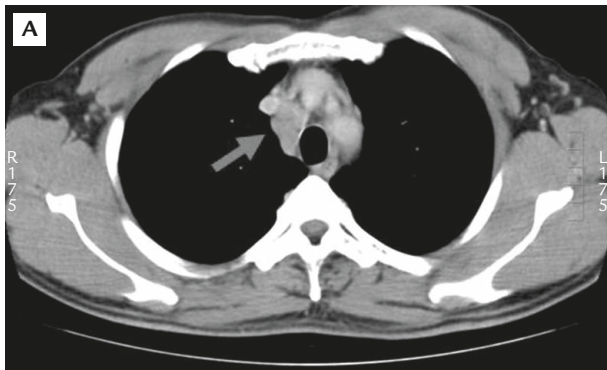


Figure 2. (A, B) Multiple enlarged mediastinal lymph nodes can be seen on chest computed tomography (arrows).

for *M. tuberculosis* was negative. Serum angiotensin-converting enzyme level was elevated to 27.2 IU/L (normal, 8.3–21.4 IU/L).

The findings of mediastinal lymph node enlargement, non-caseating granuloma, exclusion of tuberculous and fungal infections, and an elevated angiotensin-converting enzyme level led to the clinical diagnosis

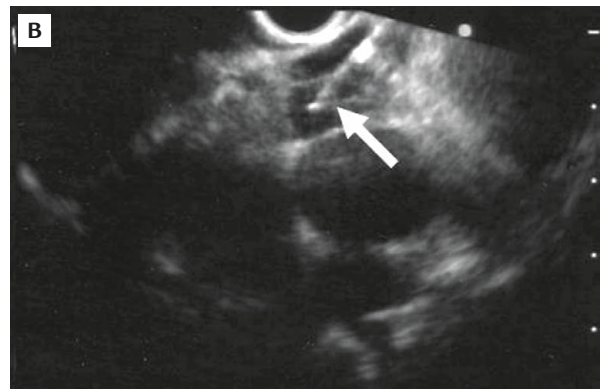
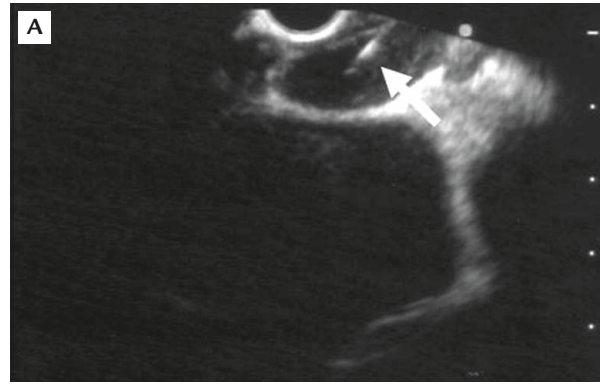


Figure 3. (A) Endoscopic ultrasound (EUS)-guided fine-needle aspiration with a 22-gauge needle (arrow) from mediastinal lymph nodes. (B) EUS-guided trucut biopsy with a 19-gauge needle (arrow) from a mediastinal lymph node.

of sarcoidosis. Lung function tests (lung volume and diffusion capacity) were normal. There were no lesions in the eyes after consultation with an ophthalmologist. The patient was given steroids, but could not tolerate the steroid therapy. He was kept under observation and followed-up for 4 months, but still had a hiccup frequency of 4–5 times a day.

Discussion

The reflex arc of a hiccup consists of an afferent pathway, including the vagus and phrenic nerves, sympathetic chain, a central mediator, and an efferent limb, including the phrenic nerve.¹ Any lesions involving this pathway can cause hiccups. There were no central nervous system, ear, throat, neck, metabolic and intra-abdominal causes in our patient to explain the etiology of hiccups, except for the finding of mediastinal lymph nodes.

Lymphoma, mediastinal cysts, and neurogenic neoplasms are the most common primary middle and posterior mediastinal tumors.³ Other lesions include

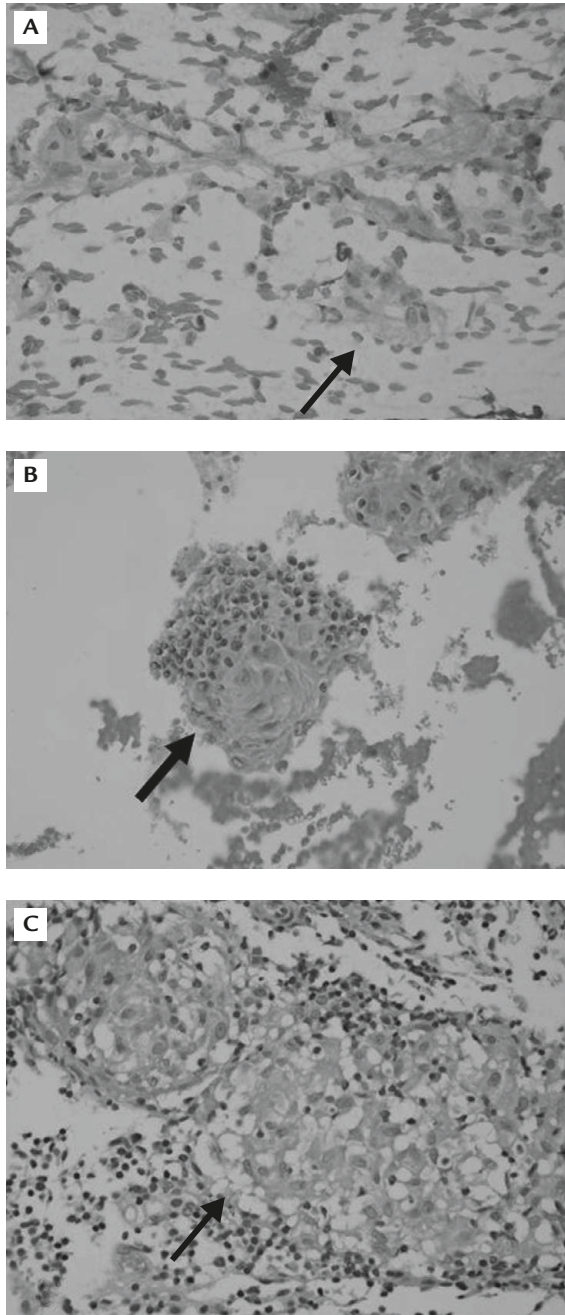


Figure 4. Non-caseating granuloma (arrows) in: (A) cytology; (B) cell block; and (C) histology.

metastatic cancers, tuberculosis and, rarely, sarcoidosis. Low-grade fever, cough, dyspnea, and arthralgia are common symptoms of sarcoidosis.⁴ Very few patients with sarcoidosis present with hiccups. The mechanism of hiccups of 2 reported cases in the literature was attributed to central nervous involvement, and the hiccups were not the initial presentations.^{5,6} To the best of our knowledge, there are no previous reports of sarcoidosis presenting solely as hiccups. Our patient presented solely with hiccups, and the cause of hiccups

was due to compression of the phrenic nerve in the mediastinum.

Diagnosis of sarcoidosis is dependent on compatible clinical and radiographic features, accompanying histological evidence of non-caseating epithelioid-cell granulomas, for which there are no apparent causative organisms or particles.^{7,8} Tissue diagnosis can be obtained from the mediastinum via EUS-FNA, rather than by mediastinoscopy. EUS-FNA can obtain granulomatous material in sarcoidosis with a high degree of accuracy,⁹⁻¹¹ and 1 retrospective study has found the sensitivity to be 89% with a specificity of 96% for EUS-FNA for diagnosing granuloma in sarcoidosis.¹² Mediastinoscopy is also more invasive than EUS-FNA, and can have a morbidity of 16%, with even 1 mortality occurring.¹³ EUS-FNA is very safe, with a complication rate of only 0.8%, as reported in a meta-analysis.¹⁴ Furthermore, EUS-guided trucut biopsy can be helpful in cases missed by EUS-FNA.¹⁵

Most patients with sarcoidosis do not require therapy. Treatment for pulmonary sarcoidosis is best guided by pulmonary-function studies.⁸ Two-thirds of patients with sarcoidosis usually have remission within a decade after diagnosis, with few consequences; more than half of patients have remission within 3 years.⁸ Fewer than 5% of patients die from sarcoidosis, and death is usually the result of pulmonary fibrosis with respiratory failure or cardiac or neurological involvement.⁸

In conclusion, gastroenterologists should be aware that mediastinal lymph node due to sarcoidosis could be a cause of hiccups.

References

1. Samuels L. Hiccup: a ten-year review of anatomy, etiology, and treatment. *Can Med Assoc J* 1952;67:315.
2. Lewis JH. Hiccups: causes and cures. *J Clin Gastroenterol* 1985;7:539-52.
3. Strollo DC, Rosado-de-Christenson ML, Jett JR. Primary mediastinal tumors: part II. Tumors of the middle and posterior mediastinum. *Chest* 1997;112:1344-57.
4. Gupta SK, Gupta S. Sarcoidosis in India: a review of 125 biopsy-proven cases from eastern India. *Sarcoidosis* 1990;7:43-9.
5. Connolly JP, Craig TJ, Sanchez RM, Sageman WS, Osborn RE. Intractable hiccups as a presentation of central nervous system sarcoidosis. *West J Med* 1991;155:78-9.
6. Kondo T, Tanigaki T, Suzuki H, Tamaya S, Ohta Y, Yamabayashi H. Long-standing hiccup in a patient with sarcoidosis. *Jpn J Med* 1989;28:212-5.
7. Baughman RP, Teirstein AS, Judson MA, Rossman MD, Yeager H Jr, Bresnitz EA, DePalo L, et al. Clinical characteristics of patients in a case-control study of sarcoidosis. *Am J Respir Crit Care Med* 2001;164:1885-9.
8. Iannuzzi MC, Rybicki BA, Teirstein AS. Sarcoidosis. *N Engl J Med* 2007;357:2153-65.

9. Mishra G, Sahai AV, Penman ID, Williams DB, Judson MA, Lewin DN, Hawes RH, et al. Endoscopic ultrasonography with fine-needle aspiration: an accurate and simple diagnostic modality for sarcoidosis. *Endoscopy* 1999;31:377-82.
10. Fritscher-Ravens A, Sriram PV, Topalidis T, Hauber HP, Meyer A, Soehendra N, Pforte A. Diagnosing sarcoidosis using endosonography-guided fine-needle aspiration. *Chest* 2000;118: 928-35.
11. Annema JT, Veselić M, Rabe KF. Endoscopic ultrasound-guided fine-needle aspiration for the diagnosis of sarcoidosis. *Eur Respir J* 2005;25:405-9.
12. Wildi SM, Judson MA, Fraig M, Fickling WE, Schmulewitz N, Varadarajulu S, Roberts SS, et al. Is endosonography-guided fine-needle aspiration (EUS-FNA) for sarcoidosis as good as we think? *Thorax* 2004;59:794-9.
13. Best LA, Munichor M, Ben-Shakhar M, Lemer J, Lichtig C, Peleg H. The contribution of anterior mediastinotomy in the diagnosis and evaluation of diseases of the mediastinum and lung. *Ann Thorac Surg* 1987;43:78-81.
14. Micames CG, McCrory DC, Pavey DA, Jowell PS, Gress FG. Endoscopic ultrasound-guided fine-needle aspiration for non-small cell lung cancer staging: a systematic review and meta-analysis. *Chest* 2007;131:539-48.
15. Eloubeidi MA, Mehra M, Bean SM. EUS-guided 19-gauge trucut needle biopsy for diagnosis of lymphoma missed by EUS-guided FNA. *Gastrointest Endosc* 2007;65:937-9.