

Case Report

Erythema Ab igne after footbath with Chinese herbal remedies

Jeng-Feng Chen^a, Ying-Chun Liu^b, Yu-Fei Chen^a, Chien-Ping Chiang^a, Wei-Ming Wang^{a,*}

^aDepartment of Dermatology, Tri-Service General Hospital, National Defense Medical Center, Taipei, Taiwan, ROC

^bNational Defense Medical Center, School of Nursing, Taipei, Taiwan, ROC

Received 29 March 2010; accepted 14 June 2010

Abstract

Erythema ab igne (EAI) is a reticulated, telangiectatic, and hyperpigmented skin eruption resulting from chronic exposure to long-term moderate heat. The incidence has decreased substantially today because of the advent of modern central heating systems. Recently, we encountered a patient who developed EAI after 2 weeks of footbaths with Chinese herbal remedies, which she used to treat her acute ankle sprain. Alternative Chinese medicine, such as herbal footbath, is a prevalent medical practice to treat acute pains as well as many chronic musculoskeletal ailments among Chinese and Asian populations. It has also become increasingly popular in Western countries in the past decade. Herein, we would like to report an uncommon case of iatrogenic EAI caused by footbath and raise the attention of clinicians to such rare, potentially malignant-transforming, dermatosis.

Copyright © 2011 Elsevier Taiwan LLC and the Chinese Medical Association. All rights reserved.

Keywords: Chinese herbal remedies; Complementary medicine; Complication; Erythema ab igne; Footbath

1. Introduction

Erythema ab igne (EAI) is a distinct skin condition characterized by localized mottled and reticular cutaneous hyperpigmentation with variable telangiectasia and skin atrophy after prolonged exposure to different sources of heat.¹ It is a historically prevalent condition of old people who spend extended time close to heaters and fireplaces, but nowadays it has become rare because of the generalized availability of central heating systems in industrialized countries. In traditional Chinese medical clinics, many complementary medical heating devices and techniques, such as heating lamp, moxibustion, and footbath with herbal remedies, are available as means to deal with many indicated conditions. These local heat therapies are generally considered to be safe and effective complementary therapies. However, we have identified a patient who developed iatrogenic EAI after herbal footbath attempting to treat her acute ankle sprain. To the best of our knowledge, a similar case has not yet been reported in the current English literature.

2. Case report

A 31-year-old Taiwanese female with no past medical history presented to our dermatology clinic with mild itchy mottled skin hyperpigmentation of her left lower leg and foot. Two weeks before this event, she had suffered from an accidental acute ankle sprain and underwent footbath with traditional Chinese herbal remedies after seeking complementary medical advice. The treatment regimen comprises warm water footbath (around 45°C–50°C in temperature) with mixed traditional Chinese herbal medicine for 30 minutes to be applied twice a day. The repeated warm water footbaths for more than 2 weeks had resulted in such reticulated skin eruption.

Physical examination revealed a net-like, brownish, mild pruritic, nontender, and nonblanchable hyperpigmentation around her left ankle and foot with two discrete coin-sized crusted erosions near the ankle and dorsal foot (Fig. 1). Skin biopsy was performed, and the specimen revealed basket-woven orthohyperkeratosis, epidermal atrophy with moderate effacement of rete ridges, loss of polarity of epidermis with discrete basal cell vacuolization, and basal cell hyperpigmentation. There were telangiectatic blood vessels in the superficial dermis with a small

* Corresponding author. Dr. Wei-Ming Wang, Department of Dermatology, Tri-Service General Hospital, 325, Sec. 2, Chenggong Rd., Neihu Dist., Taipei 114, Taiwan, ROC.

E-mail address: ades0431@ms38.hinet.net.

amount of perivascular mononuclear cell infiltration (Fig. 2). There were no immune deposits on direct immunofluorescent staining of the lesional skin. According to the clinical and histopathological findings, the diagnosis of EAI was made. The patient was advised to discontinue the footbath therapy. Consequently, the discoloration gradually lightened and itchy symptoms subsided in several months without any treatment. She was also suggested to return for checkup if she noticed any skin surface changes.

3. Discussion

EAI is a localized livedo-like red-brownish skin eruption caused by prolonged and repeated exposure to infrared radiation or moderate heat that is insufficient to produce burn injury.¹ The reticular erythema can be accompanied by variable epidermal atrophy, telangiectasia, scaling, and hyperpigmentation. Sometimes, a few superficial erosions, which are thought to be because of mild burns may be spotted.² EAI is usually asymptomatic, but some patients may report itchy or even burning sensation. The length of time necessary to develop EAI ranges from 2 weeks to several months, depending on the intensity of heat and duration of contact.^{3,4} It took only 2 weeks for our patient to develop such striking reticular hyperpigmentation characteristic to EAI. We considered that it resulted from repeated exposure and direct contact with the hot water carrying a higher temperature. In addition, certain photochemical reaction possibly occurring during the heating process might play a role in the pathogenesis of EAI. However, this speculation awaits further investigation.

EAI has been reported to result from a variety of heat sources. Historically, lesions occurred mostly on the shins of older people who spent much time close to fireplaces or coal stoves. However, such cases are rarely seen today owing to the introduction of modern central heating systems. Nevertheless, EAI is reported sporadically among people who use different kinds of heat sources, such as heating pads, furniture with built-in heating units, heating blankets, car heaters, and laptop computers.^{3–8}

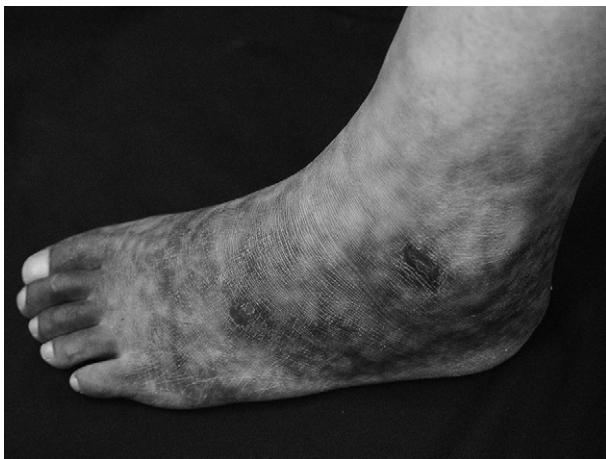

Fig. 1. Reticular and brownish hyperpigmentation around the left ankle and foot with two discrete coin-sized crusted erosions near the ankle and dorsal foot.

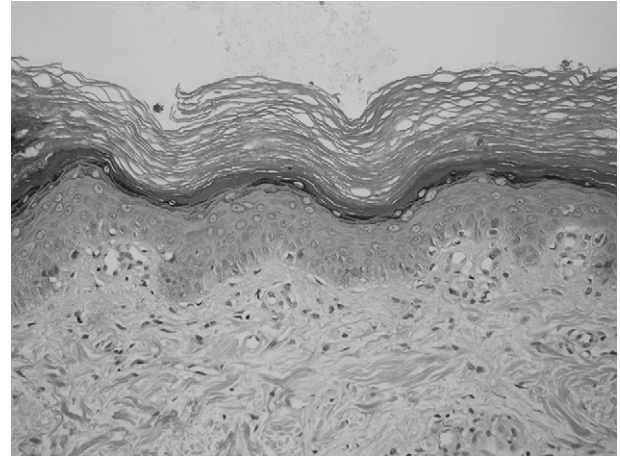


Fig. 2. Histopathology showing basket-woven orthohyperkeratosis, epidermal atrophy with moderate effacement of rete ridges, loss of polarity of epidermis with discrete basal cell vacuolization, and basal cell hyperpigmentation. There are telangiectatic blood vessels in the superficial dermis with a small amount of perivascular mononuclear cell infiltration (hematoxylin and eosin, original magnification $\times 200$).

Recently, EAI was reported as a complication after using a Sauna belt for abdominal obesity and cellulite.⁹ Surprisingly, EAI has also been stressed as an important localized sign indicative of underlying pancreatic problems because of the repeated local heat elicited by hot water bottles attempting to relieve the chronic and recurrent abdominal pain.^{10,11} Therefore, EAI developed over an unusual location, such as abdomen, should prompt clinicians to seek for pancreatitis, pancreatic pseudocyst, pancreatic cancer, splenomegaly, or other occult internal pathology. EAI lesions generally run a benign course with gradual resolution after cessation of heat contact. However, the development of thermal keratosis, squamous cell, and Merkel cell carcinomas has been reported after a long delay in diagnosis.^{12,13}

Seeking traditional Chinese medicine (TCM), an important category of complementary and alternative medicine, is common among Taiwanese and the large Chinese population in the world. The use of TCM has also increased substantially in Western countries during the past decade.¹⁴ According to a large-scale investigation, 62.5% of valid beneficiaries of the National Health Insurance in Taiwan took advantage of TCM at least once during a 6-year period from 1996 to 2001, representing a 29.2% increase of new users annually.¹⁵ Of the major TCM modalities, Chinese herbal remedies are the most popular among patients.¹⁵ They can be taken orally or put in warm water for footbathing to alleviate many musculoskeletal ailments and also to treat diabetic feet. Additionally, many other local heating therapies and techniques, such as heating lamp or moxibustion, are also commonly used in TCM. Therefore, we believe that the EAI developed from various sources of local heat therapies of TCM, although rare, may be far underreported.

This was an uncommon case of EAI resulting from footbath with herbal remedies. Generally speaking, EAI is a benign dermatosis, which may gradually fade out on discontinuation of heat exposure. Lack of clinical awareness can delay the

diagnosis and cause detrimental consequences as this skin condition may evolve into malignant skin tumors. Therefore, clinicians should be cautious about this rare complication associated with various local heat therapies. In addition, a follow-up strategy should be established to ensure early diagnosis and treatment of any possible malignant degeneration from the EAI lesions.

References

1. Finlayson GR, Sams Jr WM, Smith Jr JG. Erythema ab igne: a histopathological study. *J Invest Dermatol* 1966;**46**:104–8.
2. Chan CC, Chiu HC. Images in clinical medicine. Erythema ab igne. *N Engl J Med* 2007;**356**:e8.
3. Bachmeyer C, Bensaid P, Bégon E. Laptop computer as a modern cause of erythema ab igne. *J Eur Acad Dermatol Venereol* 2009;**23**:736–7.
4. Bilic M, Adams BB. Erythema ab igne induced by a laptop computer. *J Am Acad Dermatol* 2004;**50**:973–4.
5. Chatterjee S. Erythema Ab Igne from prolonged use of a heating pad. *Mayo Clin Proc* 2005;**80**:1500.
6. Meffert JJ, Davis BM. Furniture-induced erythema ab igne. *J Am Acad Dermatol* 1996;**34**:516–7.
7. Dellavalle RP, Gillum P. Erythema ab igne following heating/cooling blanket use in the intensive care unit. *Cutis* 2000;**66**:136–8.
8. Helm TN, Spigel GT, Helm KF. Erythema ab igne caused by a car heater. *Cutis* 1997;**59**:81–2.
9. Radmanesh M. Erythema ab igne following Sauna belt use for abdominal obesity and cellulite. *Int J Dermatol* 2009;**48**:94–5.
10. Mok DW, Blumgart LH. Erythema ab igne in chronic pancreatic pain: a diagnostic sign. *J R Soc Med* 1984;**77**:299–301.
11. Ashby M. Erythema ab igne in cancer patients. *J R Soc Med* 1985;**78**:925–7.
12. Arrington 3rd JH, Lockman DS. Thermal keratoses and squamous cell carcinoma in situ associated with erythema ab igne. *Arch Dermatol* 1979;**115**:1226–8.
13. Hewitt JB, Sherif A, Kerr KM, Stankler L. Merkel cell and squamous cell carcinomas arising in erythema ab igne. *Br J Dermatol* 1993;**128**:591–2.
14. Wolsko P, Ware L, Kutner J, Lin CT, Albertson G, Cyran L, et al. Alternative/complementary medicine: wider usage than generally appreciated. *J Altern Complement Med* 2000;**6**:321–6.
15. Chen FP, Chen TJ, Kung YY, Chen YC, Chou LF, Chen FJ, et al. Use frequency of traditional Chinese medicine in Taiwan. *BMC Health Serv Res* 2007;**7**:26.