

Case Report

Primary pelvic hydatid cyst mimicking ovarian carcinoma

Faruk Abike^{a,*}, Ilkkan Dunder^b, Omer Lutfi Tapisiz^c, Osman Temizkan^c, Banu Bingol^b,
Ahmet Payasli^c, Lale Kutluay^d

^a Department of Gynecology, Bayindir Hospital, Ankara, Turkey

^b Bilim University Faculty of Medicine, Department of Gynecological Oncology, Istanbul, Turkey

^c Dr. Zekai Tahir Burak Women Health and Research Hospital, Ankara, Turkey

^d Department of Pathology, Bayindir Hospital, Ankara, Turkey

Received February 19, 2010; accepted August 21, 2010

Abstract

Hydatid cyst is an illness that appears in consequence of the cystic form of small strap-shaped worm *Echinococcus granulosus*. Frequently, cysts exist in the lungs and liver. Peritoneal involvement is rare, and generally occurs as a result of second inoculation from rupture of a liver-located hydatid cyst. Primary ovarian hydatid cyst is very rare. A 56-year-old female patient was admitted to Emergency Service with the complaint of stomachache and swollen abdomen. From ultrasonographic examination, a right ovarian 52 × 45-mm heterogeneous semi-solid cystic mass and right hydronephrosis were detected. As a result of the tomographic examination, the right ovarian growth was judged to be a 60 × 45-mm lobule contoured, septal, heterogeneously cystic mass (ovarian carcinoma). Depending on these indicators and with the diagnosis of ovarian carcinoma, laparotomy was planned. During the observation, a mass that compressed on the right ureter and dilatation in the right ureter were determined. The mass was approximately 6 cm long and smoothly contoured, including widespread adhesions, and also obliteration of the pouch of Douglas. The mass was excised and total abdominal hysterectomy and bilateral salpingo-oophorectomy performed. After a pathological examination, hydatid cyst was diagnosed. Although pointing at the issue of the distinctive diagnosis of pelvic and peritoneal mass, it should be realized that the existence of primary peritoneal and pelvic involvement of the hydatid cyst is generally a result of the second inoculation, and is also more common in regions in which *Echinococcus granulosus* is endemic and livestock production is prevalent.

Copyright © 2011 Elsevier Taiwan LLC and the Chinese Medical Association. All rights reserved.

Keywords: Hydatid cyst; Ovarian tumor; Pelvic mass

1. Introduction

Hydatid cyst is an illness that appears in consequence of the cystic form of small strap-shaped *Echinococcus granulosus*. In general, *E. granulosus* causes a unilocular cystic illness primarily in animals such as dogs and sheeps. By way of exception, *Echinococcus multilocularis* may cause an alveolar type multilocular cystic illness in wild animals such as foxes. Frequently, this illness spreads to humans by contagion as a result of close contact with those animals. Predominantly, the

cysts are localized in the lungs and liver.^{1–3} It has been reported that of 1,164 patients operated on for hydatid cyst, 764 had hepatic involvement, 240 had pulmonary involvement, and 160 had involvement of other organs. On the other hand, multiorgan involvement occurs in less than 2% of all cases.⁴ Detection of a peritoneal localized hydatid cyst is very rare.⁴ Among the operations of 532 hydatid cyst cases, only 12 of those were primarily peritoneal localized, and only 2 of those had uterine localization.⁵

2. Case report

A 56-year-old female patient was admitted to Emergency Service with the complaint of stomachache and swollen

* Corresponding author. Dr. Faruk Abike, Department of Gynecology, Bayindir Hospital Ankara, Department of Obstetrics and Gynecology, 06200 Ankara, Turkey

E-mail address: farukabike@gmail.com (F. Abike).

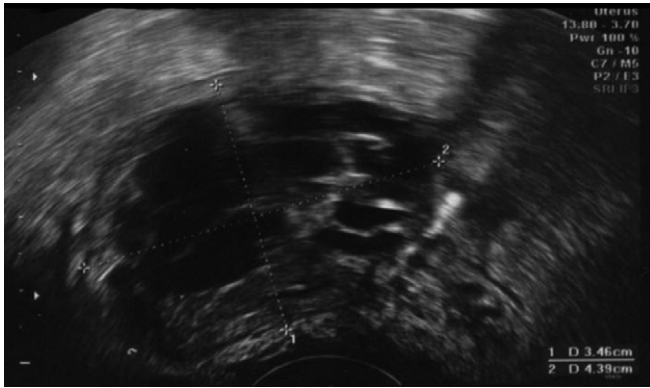


Fig. 1. Ultrasonographic image of pelvic semi-solid mass.

abdomen. She also mentioned that she lived in a village and worked in cow-feeding. In the first evaluation, she displayed sensitivity in the lower part of her abdomen and pelvic region. In consequence of the gynecologic examination, it was established that she had a right adnexal sensitivity and fixed mass. At the same time, the blood count and biochemical serum parameters of the patient were within normal limits.

The patient's C-reactive protein level was 12.8 mg/L. In the ultrasonographic evaluation, a 52 × 45-mm heterogeneous formed semi-solid cystic mass was found on the right ovary (Fig. 1), and right hydronephrosis was determined. As a result of the tomographic evaluation, the ovarian growth was confirmed as a 60 × 45-mm lobule contoured, septal heterogeneous cystic mass (suspect of ovarian carcinoma). CA 125 level was 139 U/L. Based on these results with the diagnosis of carcinoma, a laparotomy was scheduled.

Midline incision was performed to open up the abdomen. In the observation, a mass 6 cm in origin from the right ovarium, smooth contoured, with many adhesions and obliterating the pouch of Douglas, compressing on the right ureter was found. There was also a dilatation on the right ureter. The mass was excised in conjunction with total abdominal hysterectomy and bilateral salpingo-oophorectomy. During the operation, a frozen section was taken (Figs. 2 and 3). After the frozen section was evaluated as being benign, the abdomen was closed up. In the post-operative pathological and microbiological examination period, because of the *E. granulosus* and hydatid cyst result, the patient was referred to the Department of Infectious Disease. Serum Echinococcus Hemagglutination test

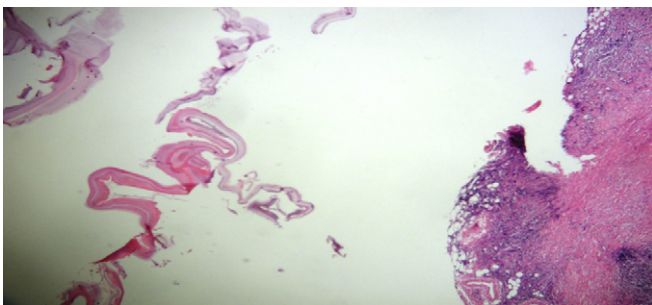


Fig. 2. Basophilic laminar membrane, fibrosis and mononuclear cell infiltration in cyst wall (hematoxylin & eosin, ×40).

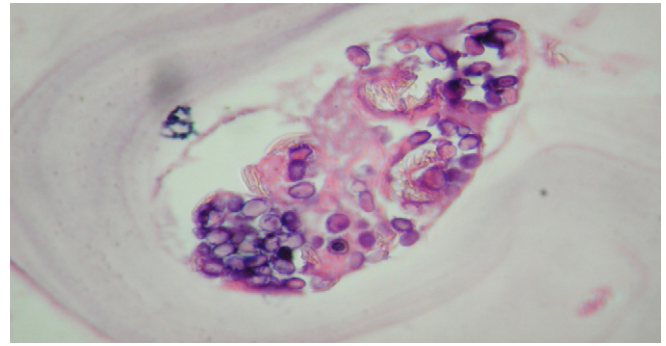


Fig. 3. Degenerated scolex (hematoxylin & eosin, ×400).

in 1/2,048 in titer was positive, and the level of Echinococcus Ig E was 43.4 kU/L (++++). CA 125 was 32 U/L during the post-operative period. Albendazole (Andazol 200 mg, Biofarma) 2 × 400 mg was given to the patient. Later the patient was followed-up by the Department of Infectious Diseases. On the third post-operative day, the patient was discharged.

3. Discussion

Hydatid cyst is a parasitic infection caused by the *E. granulosus* worm. Infection arises particularly after close contact with animals such as dogs and sheep. The infection is endemic in regions in which animal husbandry is prevalent. The localization of the hydatid cyst is frequently in the liver and lungs. Primary peritoneal involvement is uncommon; generally, peritoneal invasion arises as a result of second inoculation after the rupture of hydatid cyst in the liver.^{1–4}

Hydatid cyst is composed of three layers. The outer layer (pericyst) has a fibrous tissue and is gray. Generally, pericyst arises as a result of chronic inflammatory reaction in consequence of the host's immune system activation. Hydatid cyst located in the liver or spleen has slighter pericysts when compared with the peritoneal localized cysts. Hydatid cysts which are located in brain and lungs have no pericysts. Pericysts may be classified and may exhibit contrast on radiological graphics. There exists a laminar membrane (ectocyst) and germinal membrane (endocyst) layers under the pericyst. Vital layer is an endocystic region that involves parasites. Hydatid cyst involves very antigenic and toxic liquid which is transparent and alkaline. The cyst grows very slowly and generally is asymptomatic until it reaches large dimensions. There can be observed an anaphylactic reaction as a result of cyst rupture, or the growing cyst may cause an obstruction as it compresses on neighboring tissue and organs.⁶ The primary peritoneal hydatid cyst is seen rarely that is generally *E. granulosus* embryos passed to the portohepatic circulation then emplace to retroperitoneal lymph nodes or direct placement of lymph nodes in gastrointestinal system.⁷

The outstanding technique for the diagnosis of hydatid cyst is ultrasonography with tomography. Ultrasonography is cost-effective in endemic areas and when the diagnosis of hydatid cyst is certain. It helps to determine the location and dimension of the cyst. However, ultrasonography is less accurate in localizing and delineating the extent of the cyst. However,

tomography can identify hydatid cyst with 90% sensitivity.⁸ Primary peritoneal hydatid cyst invasion is rare, the percent of such invasion in Turkey is under 2%.⁹ Most effective in hydatid cyst treatment is albendazol, which is recommended as treatment of the pre-operative and post-operative periods. Pre-operative application of albendazol reduces post-operative recurrence. It is recommended to continue with the pre-operative, 5th day and post-operative albendazol treatment. The recurrence ratio after surgical treatment has been reported to be approximately 2%.¹⁰

Although primary peritoneal and pelvic involvement of the hydatid cyst generally arise with the second inoculation, the distinctive feature of pelvic and peritoneal mass should be considered for regions where *E. granulosa* is endemic and animal husbandry is widespread. It could be diagnosed missing as ovarian or peritoneal carcinoma at the pre-operative period.

References

1. Bannister B, Begg N, Gillespie S. *Infectious disease*. 2nd ed. United Kingdom: Blackwell Science; 2000. p. 506.
2. Gueddana F, Chemmen Lebbene L, Lebi I, Koubaa A, Benzined T, Benjlani S. Intrauterine hydatidosis: a case report. *J Obstet Gynecol Reprod Biol* 1990;**19**:725–7.
3. Komongui DG, Diouf A, Dao B, Gentile B, Bah MD, Diadhiou F. Hydatid cyst of the uterus (apropos of a case seen at the gynecologic and obstetrical clinic of the C.H.U. of Dakar). *Dakar Med* 1990;**35**:162–7.
4. Tarcoveanu E, Dimofte G, Bradea C, Crumpei F, Anton R, Moldovanu R. Multiple peritoneal hydatid disease after rupture of a multivesicular hepatic hydatid cyst: case report. *J Gastrointestin Liver Dis* 2006;**15**:301–5.
5. Bickers WM. Hydatid disease of the female pelvis. *Am J Obstet Gynecol* 1970;**107**:477–83.
6. Milicevic M. Hydatid disease. In: Blumgart LH, editor. *Surgery of the liver and biliary tract*. 2nd ed. New York: Churchill Livingstone; 1994. p. 1121–50.
7. Salvaggi FP, Fabiano G, Santacroce S, Tragicante A. A retrovesical echinococcal cyst: unusual case of acute urinary retention. *Eur Urol* 1978;**4**:60–2.
8. Safioleas M, Misiakos E, Manti C, Katsika D, Skalkeas G. Diagnosis evaluation and surgical management of hydatid disease of the liver. *World J Surg* 1994;**18**:859–65.
9. Unal S, Kayhan B, Balos F, Görgül A. Primary pelvic hydatid cyst. *J Clin Gastroenterol* 1996;**23**:303–4.
10. Guidelines for treatment of cystic and alveolar echinococcosis in humans. WHO informal working group on Echinococcosis. *Bull World Health Organ* 1996;**74**:231–42.