

Case Report

Hemopericardium from right atrial laceration in a newborn

Wen-Hsien Lu^{a,b}, Ying-Yao Chen^a, Jun-Yen Pan^c, Hsiao-Ping Wang^a,
Jenn-Tzong Chang^a, Kai-Sheng Hsieh^{a,*}

^aDepartment of Pediatric Cardiology, Kaohsiung Veterans General Hospital, Kaohsiung and National Yang-Ming University School of Medicine, Taipei, Taiwan, ROC

^bInstitute of Aerospace Medicine, National Defense Medical Center, Taipei, Taiwan, ROC

^cDepartment of Cardiovascular Surgery, Kaohsiung Veterans General Hospital, Kaohsiung, Taiwan, ROC

Received September 24, 2010; accepted December 9, 2010

Abstract

We report the case of a newborn who suffered right atrial laceration during delivery. To our knowledge, there has been no previous report of blunt injury causing right atrial laceration with hemopericardium complicated by cardiac tamponade in the perinatal period. Copyright © 2011 Elsevier Taiwan LLC and the Chinese Medical Association. All rights reserved.

Keywords: blunt injury; hemopericardium; newborn; shoulder dystocia

1. Introduction

Hemopericardium, defined as the accumulation of blood in the pericardial space, will cause cardiac tamponade. It can occur in rupture of an aortic aneurysm, during the course of cancer, with penetration injuries, etc. It rarely occurs from rupture of the heart in response to blunt injury. The prognosis usually is unfavorable, even with judicious treatment.^{1,2} To the best of our knowledge, there has been no report on right atrial laceration during the perinatal period as a result of blunt injury.

2. Case report

In February 2010, a female baby weighing 4000 g was born at a local obstetric hospital by normal spontaneous delivery after induction because the baby had already attained a normal size at the 39th week of gestation. Her 31-year-old mother (gravida 4, para 2, abortion 1) did not have any systemic

disease during the pregnancy, and the results of a prenatal examination conducted before labor were normal.

During labor, the mother experienced shoulder dystocia and underwent a difficult and prolonged labor. After birth, the baby had no heart beat or respiratory rate, was flaccid, and showed cyanosis. The baby had perinatal asphyxia with Apgar scores of 0, 1, and 1 at 1, 5, and 10 minutes after birth, respectively. Cardiopulmonary resuscitation was performed immediately at the local obstetric hospital with endotracheal tube insertion, and the baby was given mechanical ventilatory support. Epinephrine was also administered.

About half an hour later, the baby was transferred to our neonatal intensive care unit (NICU) at Kaohsiung Veteran General Hospital, Taiwan to continue resuscitation until her heart beat returned. At our hospital, echocardiography revealed normal cardiac structures but pericardial effusion with suspected bloody fluid (Fig. 1), and the patient's condition was diagnosed as cardiac tamponade with cardiogenic shock. We performed subxiphoid pericardial drainage and drained 44 mL of blood. The patient's condition remained, however, unstable. We repeated echocardiography and found no remission of fluid accumulation over the pericardium.

After consulting a cardiovascular surgeon, median sternotomy and pericardiotomy were performed at the bedside.

* Corresponding author. Dr. Kai-Sheng Hsieh, Department of Pediatric Cardiology, Kaohsiung Veterans General Hospital, 386, Ta-Chung 1st Rd., Kaohsiung 813, Taiwan, ROC.

E-mail address: lu6802@gmail.com (K.-S. Hsieh).

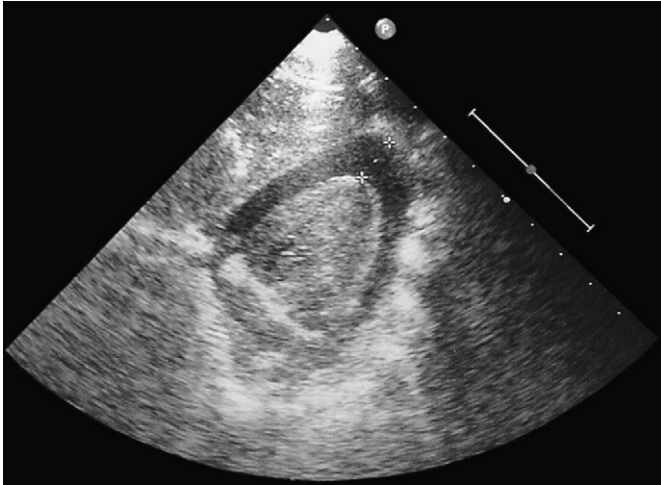


Fig. 1. Pericardial effusion noted by echocardiography.

During the operation, after aspirating the blood inside the pericardium, we found a 1-cm laceration and active bleeding over the right atrium near the inferior vena cava. In our NICU, a brain sonogram showed increased echogenicity in the parenchyma, no obvious intraventricular hemorrhage or cyst formation, no midline shift, and no subdural effusion. A chest radiograph showed cardiomegaly and no rib fracture or pleural effusion (Fig. 2).

Laboratory data were as follows: serum glutamate oxaloacetate transaminase, 129 U/L; glutamate pyruvate transaminase, 36 U/L; creatine kinase, 1385 U/L; creatine kinase-MB fraction, 1146 U/L; troponin I, 6.083 ng/mL; C-reactive protein, 0.5 mg/dL; white blood cell count, $16.28 \times 1000/\text{mm}^3$; hemoglobin, 11.2 g%; and hematocrit, 36.2%.

Unfortunately, although we continued resuscitation with cardiac massage, administration of inotropic agents, and blood transfusion, the baby expired 1 hour after primary repair of the right atrium.

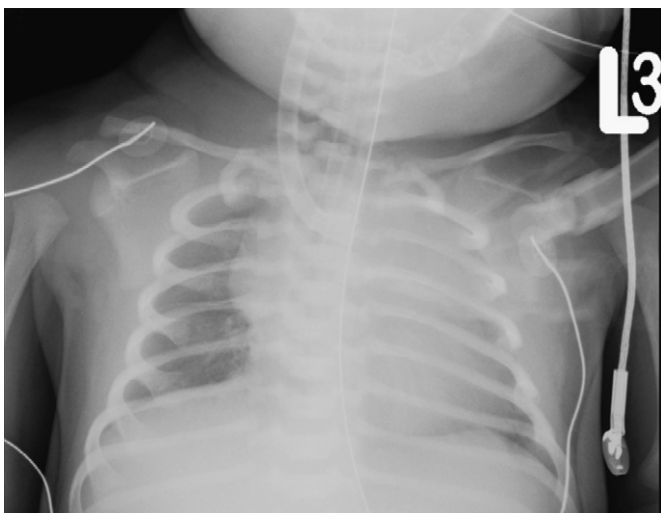


Fig. 2. Chest x-ray film showing cardiomegaly.

3. Discussion

This is the first case report of right atrial laceration during the perinatal period. In this case, the hemopericardium may have been caused by the blunt chest injury after the difficult birth with shoulder dystocia and/or resuscitation after birth with asphyxia. The early detection of hemopericardium in the delivery room will contribute to better patient care in the future.

Even in adults, cardiac rupture after a blunt injury to the chest commonly causes death at the scene, and the condition is thus rarely encountered by clinicians. Cardiac tamponade is the most common feature of blunt traumatic cardiac rupture; however, the diagnosis of cardiac tamponade may be delayed because of the temporary coexistence of other unstable clinical manifestations.¹ Beck's triad of muffled heart sounds, an engorged jugular vein, and hypotension is not detected easily in a newborn baby in cardiogenic shock. With blunt chest injury, the common sites of traumatic cardiac rupture are the right atrium, left ventricle, right ventricle, left atrium, inter-ventricular septum, and valves.²

The possible mechanisms of injury to the heart in blunt chest injury are: (1) the direct transmission of a sudden rise in intrathoracic or intracardiac pressure to the chambers of the heart; (2) a hydraulic effect produced when a large external force is applied to the veins of the abdomen or an extremity, and the force is transmitted to the right atrium, resulting in rupture; (3) a rapid deceleration force leading to atriocaval tears and disruption of the connections to the superior or inferior vena cava and pulmonary veins situated at the atrial junction; (4) myocardial contusion, ischemia, necrosis, and subsequent cardiac rupture; (5) penetration of the heart (fracture of the ribs or sternum, and bullet wounds); and (6) as an iatrogenic complication.^{1,3–5}

In conclusion, the results of prenatal examinations showed that the baby was normal, and the mother had planned to deliver the baby by normal spontaneous delivery. No heart beat or respiratory rate was noted after birth, and the baby had perinatal asphyxia because of shoulder dystocia during delivery. Right atrial laceration with hemopericardium complicated by cardiac tamponade was possibly the result of shoulder dystocia and/or resuscitation after birth. This is the first case report on hemopericardium in the perinatal period. Early suspicion of hemopericardium in perinatal asphyxia may be essential for a better outcome.

References

1. Nan YY, Lu MS, Liu KS, Huang YK, Tsai FC, Chu JJ, et al. Blunt traumatic cardiac rupture: therapeutic options and outcomes. *Injury* 2009;**40**:938–45.
2. Biggart JD, McClure J. Right atrial laceration. Complication of external cardiac massage. *Br Heart J* 1975;**37**:652–5.
3. Fulda G, Brathwaite CE, Rodriguez A, Turney SZ, Dunham CM, Cowley RA. Blunt traumatic rupture of the heart and pericardium: a ten-year experience (1979–1989). *J Trauma* 1991;**31**:167–72.
4. Dent LL, Lee A. Survival of blunt cardiac rupture after asystolic arrest: a case report. *J Trauma* 2009;**66**:1246–7.
5. Meisel S, Ram Z, Priel I, Nass D, Lieberman P. Another complication of thoracostomy: perforation of the right atrium. *Chest* 1990;**98**:772–3.