

Case Report

En bloc surgical removal of an asymptomatic glomus tympanicum tumor

Ying-Liang Chou, Bor-Rong Huang, Chih-Hung Wang*

Department of Otolaryngology-Head and Neck Surgery, Tri-Service General Hospital, National Defense Medical Center, Taipei, Taiwan, ROC

Received October 26, 2010; accepted December 1, 2010

Abstract

Glomus tympanicum (GT) tumors are usually characterized by pulsatile tinnitus and hearing loss. We report on a woman 53 years of age who was diagnosed with a GT tumor within her right ear with no associated tinnitus or hearing loss on presentation. An early GT tumor without the characteristic symptoms is seldom encountered. Although several papers have dealt with GT tumor diagnosis and management, very few have demonstrated such a condition in which the entire GT tumor appeared in the middle ear cavity and was totally removed during the operation. There was no recurrence at 24 months of follow-up. We describe a novel surgical technique in this article and demonstrate an en bloc GT surgical removal that has been seldom published before in the literature.

Copyright © 2011 Elsevier Taiwan LLC and the Chinese Medical Association. All rights reserved.

Keywords: glomus tympanicum; GT; hearing loss; paraganglia; surgery; tinnitus; tumor

1. Introduction

Glomus tympanicum (GT) tumors are paragangliomas in the middle ear that arise from paraganglia, or glomus bodies.¹ Glomus bodies are specialized organelles distributed along the course of autonomic nerves throughout the body.² The function of most glomus bodies in the head and neck is obscure except for the carotid body, which is a chemoreceptor.¹ In the temporal bone, glomus bodies are found commonly in the mesotympanum and usually accompany the tympanic (or Jacobson's) nerve, which is a branch of the glossopharyngeal nerve.³ GT tumors are benign neoplasms that these tumors commonly exhibit when diagnosis is delayed. Tinnitus and hearing loss are characteristic clinical manifestations and can be seen in most patients whose tumors have expanded and compressed in the adjacent structures of the middle ear. We present an early GT tumor and briefly discuss the management as well as the related literature. This case report has been approved by our hospital's Institutional Review Board.

2. Case report

A woman who was 53 years of age was referred to our clinic because of a red mass lesion behind her right eardrum that was noted during a physical examination. Her previous medical history included chronic renal failure and she was being treated with regular hemodialysis. There was no hearing loss or aural discomfort, and there were no pulsatile tinnitus complaints. Clinical examination revealed a pulsating red mass located behind the inferior half of the tympanic membrane (Fig. 1). Pure tone audiometry measured the patient's hearing threshold and revealed no significant impairment across all frequencies. Since the lesion of the mass was limited between the promontory and tympanic membrane, which was demonstrated by a high-resolution computed tomography (CT) of the temporal bone (Fig. 2) and measured 3.5×3 mm in size, an exploratory tympanotomy was performed via an endaural approach. By elevating the tympanic membrane, the tumor mass could be well identified and distinguished from the circumferential mucosa lining the middle ear cavity (Fig. 3). Thus, tumor removal was begun by soaking the tumor border in diluted epinephrine sponge, followed by separating the promontory mucosa 1 mm away from the tumor margin peripherally. An en bloc tumor resection without significant bleeding was achieved because the

* Corresponding author. Dr. Chih-Hung Wang, Department of Otolaryngology-Head and Neck Surgery, Tri-Service General Hospital, National Defense Medical Center, 325, Section 2, Cheng-Kung Road, Taipei 114, Taiwan, ROC.

E-mail address: chw@ms3.hinet.net (C.-H. Wang).

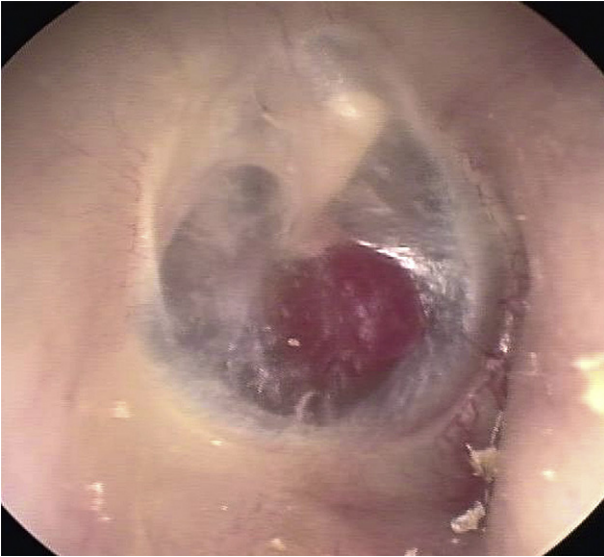


Fig. 1. A pulsating red mass is seen behind the inferior half of the tympanic membrane.

tumor and the associated feeding vessels were shrunk by the diluted epinephrine sponge (Fig. 4). No coagulation was used during operation. Histologic examination revealed the diagnostic features of paraganglioma. Neither tumor recurrence nor postoperative hearing deterioration was found at 24 months of follow-up.

3. Discussion

Although GT tumors are recognized as the most common primary neoplasm of the middle ear, they exhibit a challenging

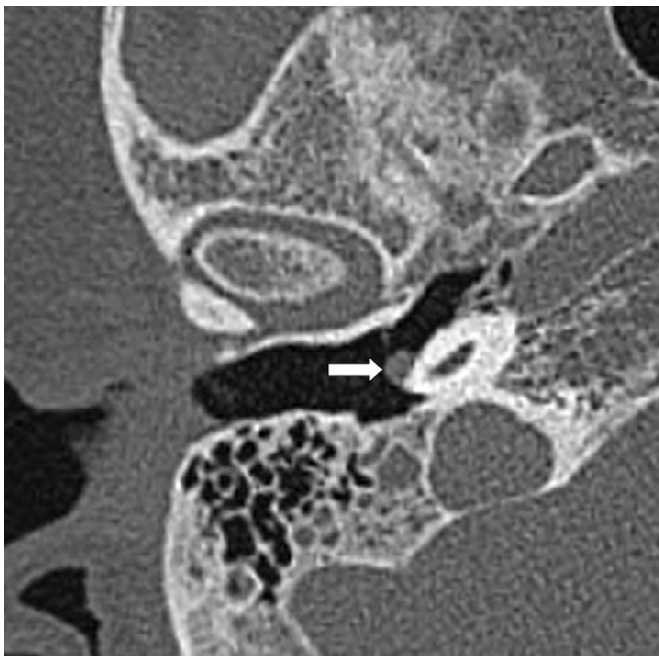

Fig. 2. An axial computed tomography scan demonstrates that the glomus tympanicum tumor (arrow point) is located on the promontory.

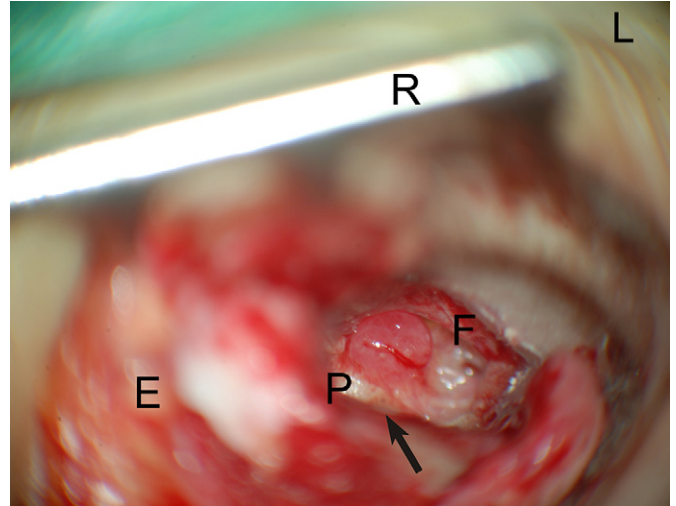


Fig. 3. After raising the tympanomeatal flap, a red smooth mass covered by one branch of feeding vessels was fully exposed on the promontory, just anterior and inferior to the round window niche (arrow point). E = endaural incision; F = anteriorly reflected tympanomeatal flap; L = ear lobe; P = promontory; R = retractor.

diagnostic evaluation and therapy. Differential vascular middle ear masses commonly include an aberrant carotid artery, facial nerve neuroma, and high jugular bulb.^{4,5} The tumor appearance and its location in the middle ear cavity helped to provide initial signs as to the histological origin. High-resolution temporal bone CT provided a high correlation between fine structure involvement and the inferred diagnosis, and it seems to be superior to magnetic resonance imaging in radiologic evaluation choices.^{4,6}

Surgery is recommended for the management of GT tumors, although intraoperative troublesome bleeding is frequently encountered.⁶ Rohit and colleagues³ reported on a surgical technique to treat a series of 17 GT tumor cases. They used bipolar cautery to shrink and mobilize the tumor in the middle ear. In this case, we applied a diluted epinephrine sponge to the tumor border before resection. It did facilitate

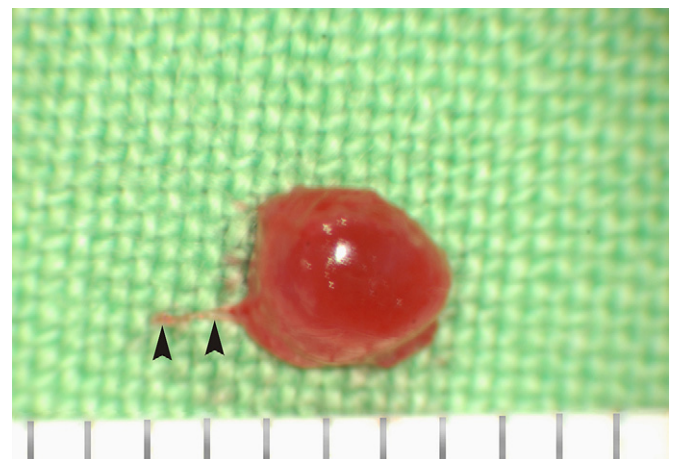


Fig. 4. The tumor mass accompanying Jacobson's nerve (arrowheads) was en bloc removed.

the blocking of the feeding vessels during dissection by blenched the tumor without the need for cauterization. We believe that this technique is also helpful in providing better exposure of the tumor when dealing with larger tumors than the one treated in our case. Once the tumor is fully exposed, we recommend that the dissection be started from the peripheral intact mucosa to avoid direct manipulation of the tumor and subsequent bleeding.

Laser excision provides an alternative treatment modality. Both potassium-titanyl-phosphate (KTP) and diode lasers have been successfully applied in GT tumor excision without peri- or postoperative complications.^{7,8} The most distinct advantages of the laser are its excellent coagulative properties and minimal mechanical trauma. The ability to coagulate the blood vessel and shrink the tumor volume allows the laser to offer better surgical field visualization. However, energy transmission into the inner ear has always been a great concern. Postoperative sensorineural hearing loss has been reported when using the neodymium-doped yttrium aluminium garnet laser,⁹ but not KTP or diode laser, in GT tumor excision.

In conclusion GT tumors are usually characterized by pulsatile tinnitus and hearing loss.⁴ Our case presented an early GT tumor without the characteristic symptoms, a situation that is seldom encountered. Although several papers have dealt with GT tumors diagnoses and management, very few have demonstrated the entire GT tumor picture in the middle

ear cavity during the operation, nor an en block gross view of the resected tumor. We have described a novel surgical technique and have shown an entire visualized GT tumor picture seldom before published in the literature.

References

1. Weissman JL, Hirsch BE. Beyond the promontory: the multifocal origin of glomus tympanicum tumors. *Am J Neuroradiol* 1998;**19**:119–22.
2. Noujaim SE, Pattekar MA, Cacciarelli A, Sanders WP, Wang AM. Paraganglioma of the temporal bone: role of magnetic resonance imaging versus computed tomography. *Top Magn Reson Imaging* 2000;**11**:108–22.
3. Rohit Jain Y, Caruso A, Russo A, Sanna M. Glomus tympanicum tumour: an alternative surgical technique. *J Laryngol Otol* 2003;**117**:462–6.
4. O'Leary MJ, Shelton C, Giddings NA, Kwartler J, Brackmann DE. Glomus tympanicum tumors: a clinical perspective. *Laryngoscope* 1991;**101**:1038–43.
5. Schickschneit M, Maier W, Kayser G, Berlis A, Boedeker CC. Amputation neuroma of the middle ear mimicking glomus tympanicum tumor. *Otolaryngol Head Neck Surg* 2007;**137**:843–4.
6. Forest III JA, Jackson CG, McGrew BM. Long-term control of surgically treated glomus tympanicum tumors. *Otol Neurotol* 2001;**22**:232–6.
7. Durvasula VS, De R, Baguley DM, Moffat DA. Laser excision of glomus tympanicum tumours: long-term results. *Eur Arch Otorhinolaryngol* 2005;**262**:325–7.
8. Molony NC, Salto-Tellez M, Grant WE. KTP laser assisted excision of glomus tympanicum. *J Laryngol Otol* 1998;**112**:956–8.
9. Robinson PJ, Grant HR, Bown SG. NdYAG laser treatment of a glomus tympanicum tumour. *J Laryngol Otol* 1993;**107**:236–7.