

Case Report

# Neck mass as the first presentation of metastatic prostatic adenocarcinoma

Yuan-Yung Lin, Deng-Shan Lin, Bor-Hwang Kang, Yaoh-Shiang Lin\*

Department of Otolaryngology, Head and Neck Surgery, Tri-Service General Hospital, National Defense Medical Center, Taipei, Taiwan, ROC

Received December 25, 2009; accepted December 15, 2010

## Abstract

Adenocarcinoma of the prostate (CAP) is a rare diagnosis in men younger than 50 years of age; this age group accounts for less than 0.1% of all patients with prostatic cancer. Left supraclavicular lymphadenopathy (LSCL) as the presenting symptom of metastatic CAP is even rarer. No cases of CAP presenting as LSCL in men younger than 45 years have been reported in the literature. Here we report a 42-year-old male with the uncommon presentation of CAP as LSCL. In adult males with persistent LSCL, even if younger than 45 years, measurement of serum prostate specific antigen is warranted at the time of initial presentation, and the lymph node biopsy should be subsequently stained for prostate specific antigen immunohistochemically. These examinations are crucial to establish a definitive diagnosis of CAP and, in turn, to institute appropriate management and achieve the best possible outcome.

Copyright © 2011 Elsevier Taiwan LLC and the Chinese Medical Association. All rights reserved.

*Keywords:* adenocarcinoma of prostate; digital rectal examination; lymphatic metastasis; prostate-specific antigen

## 1. Introduction

Cervical lymph nodes are a common site of metastasis for head and neck malignancy, and cancers originating from the other sites can also metastasize to these nodes. Adenocarcinoma of the prostate (CAP) is known to metastasize to cervical nodes, and should be considered in the differential diagnosis of neoplastic lesions of the head and neck.<sup>1,2</sup>

CAP is the most common noncutaneous human malignancy, with an estimated 186,320 new cases in the USA in 2008. It is also the second-most lethal tumor among men, with 28,660 expected deaths in 2008.<sup>3</sup> In Taiwan, CAP is the fifth-most common cancer and the seventh-leading cause of cancer death in men.<sup>4</sup> It is rarely diagnosed in men younger than 50 years of age; this age group accounts for less than 0.1% of all patients with CAP. Peak incidence of CAP occurs between the ages of 70 and 74 years, with 85% diagnosed after the age of

65 years.<sup>5</sup> Age at diagnosis among men with prostate cancer continues to fall, and the proportion of young men with prostate cancer continues to rise as a result of the current and evolving practices of screening and treatment. Lin et al reported that men who were younger than 55 years at diagnosis increased from 2.3% between 1988 and 1991 to 9% between 2000 and 2003, whereas the median age at diagnosis decreased from 72 years in 1988 to 68 years in 2003.<sup>6</sup> The incidence of CAP metastatic to the supraclavicular lymph nodes is rare, with a reported rate of approximately 0.28%.<sup>7</sup> The prognosis of metastatic CAP to the head and neck can be relatively good, with the possibility of prolonged survival after appropriate diagnosis and treatment.<sup>2,8,9</sup>

Review of the literature suggests that in patients with neck masses, CAP should be ruled out if the patients are older than 45 years of age. This case report highlights the need for a high index of suspicion of CAP in patients with neck masses, even if they are younger than 45 years old.

## 2. Case report

A 42-year-old healthy Taiwanese male presented with a 2-month history of persistent, palpable, and painless masses of

\* Corresponding author. Dr. Yaoh-Shiang Lin, Department of Otolaryngology, Head and Neck Surgery, Tri-Service General Hospital, 325, Section 2, Cheng-Kung Road, Taipei 114, Taiwan, ROC.

E-mail address: [yaohshiang@gmail.com](mailto:yaohshiang@gmail.com) (Y.-S. Lin).

the left side of his neck. He denied any other subjective complaints, including difficult swallowing, breathing, or bladder symptoms. His past medical and family history were unremarkable. He had a 20-year history of smoking, drinking alcohol and betel nut chewing.

Physical examination revealed two round, palpable, fixed, firm and non-tender masses in the left supraclavicular fossa, with the largest one measuring approximately  $3 \times 2$  cm and the smaller one  $2 \times 1$  cm. Examination of the chest and abdomen were unremarkable. On physical examination, the pubic and groin region, external genitalia, scrotum and testes were unremarkable. Digital rectal examination (DRE) was not performed at that time.

Laryngoscopy and nasopharyngoscopy showed normal smooth mucosa of the oropharynx, hypopharynx and nasopharynx. X-ray of the chest and kidneys–ureters–bladder (KUB) were unremarkable. Routine blood biochemistry and thyroid function tests were within the normal range. Urinalysis and ultrasound imaging of the abdomen were unremarkable. Computed tomography (CT) of the neck showed a cluster of enlarged lymph nodes involving the left supraclavicular fossa (Fig. 1). Fine-needle aspiration biopsy revealed small clusters of abnormal cells with a high nucleus-to-cytoplasm ratio, suggestive of malignancy. Rigid endoscopy of the upper aerodigestive tract showed normal findings. Excisional biopsy of the left neck masses revealed poorly differentiated metastatic adenocarcinoma of undetermined origin (Fig. 2).

Serum tumor markers were examined in an attempt to identify the primary lesion, revealing a prostate-specific antigen (PSA) level of 153 ng/mL (normal  $< 4.0$  ng/mL). The pathologist was informed of the elevated PSA, and subsequent immunohistochemical staining of the left supraclavicular lymph nodes was positive for PSA (Fig. 3). DRE revealed a stony hard

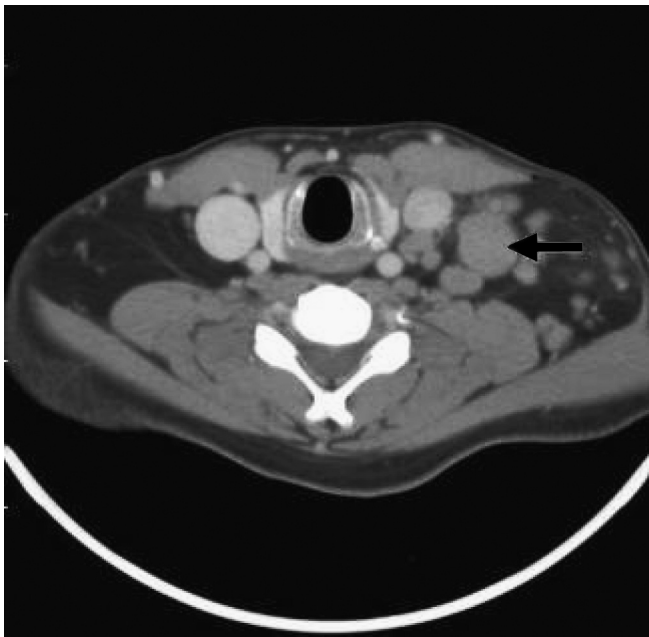


Fig. 1. Computed tomography scan of neck demonstrating a cluster of enlarged lymph nodes involving the left supraclavicular fossa, with the largest one measuring 2 cm in short axis (arrow).

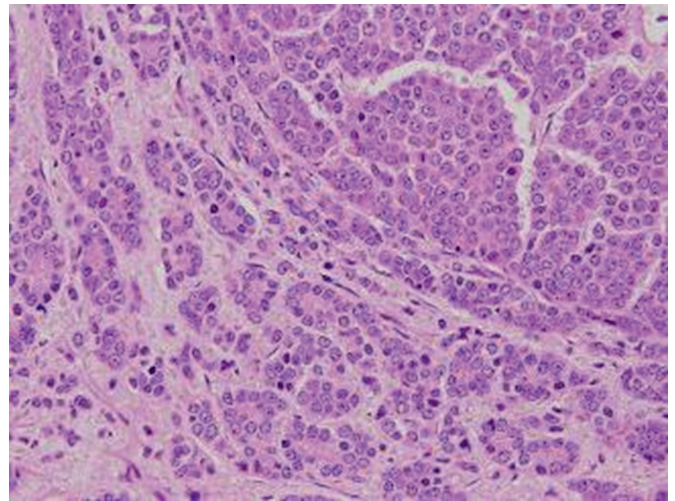


Fig. 2. Excision biopsy of the left neck masses showing a poorly differentiated metastatic adenocarcinoma of undetermined origin, comprised of malignant cells with vesicular nuclei and prominent nucleoli (hematoxylin and eosin stain, original magnification  $\times 400$ ).

prostate with grade 2 enlargement. Transrectal ultrasound-guided needle biopsy of the prostate demonstrated adenocarcinoma (Gleason score  $5 + 5 = 10$ ) (Fig. 4). A bone scan revealed multiple bony metastases. CT of the abdomen and pelvis showed multiple lymphadenopathy in the para-aortic and paracaval regions, bilateral common iliac chain, and bilateral internal and external iliac chain. Hormonal therapy was initiated, and the patient subsequently underwent bilateral orchiectomy. Four months later, his LSCL had regressed and serum PSA had decreased to 0.71 ng/mL. He remained without evidence of recurrent disease 15 months after treatment.

### 3. Discussion

The most common sites of metastasis of CAP are regional lymph nodes and bones, followed by lung, bladder, liver,

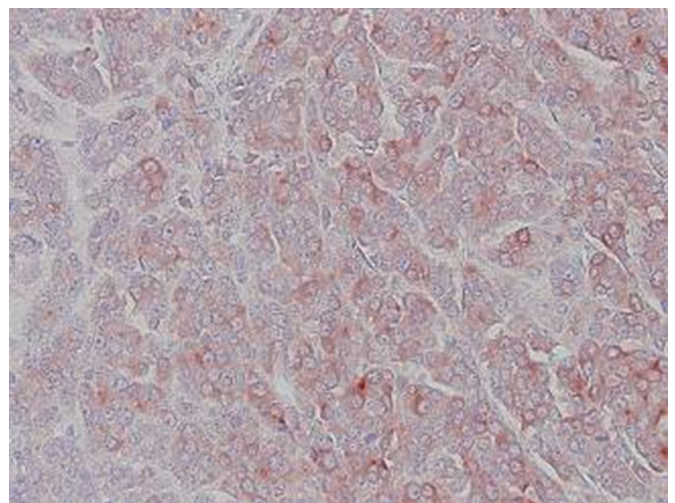


Fig. 3. Immunohistochemical staining of the neoplastic cells from the left supraclavicular lymph nodes, showing strong positivity for prostate-specific antigen (PSA) (PSA stain, original magnification  $\times 400$ ).



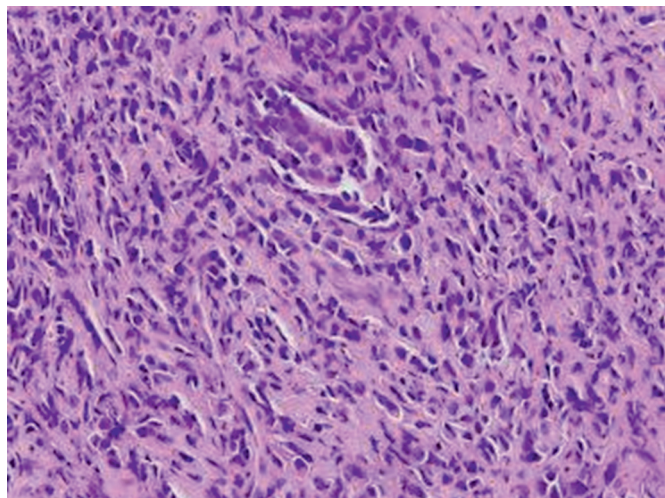


Fig. 4. Transrectal ultrasonographic-guided needle biopsy of prostate demonstrating adenocarcinoma (Gleason score 5 + 5 = 10) (hematoxylin and eosin stain, original magnification  $\times 400$ ).

adrenal gland and kidney. Lymphatic dissemination most frequently involves regional lymph nodes of the retroperitoneum and pelvic cavity, followed by the para-aortic lymph nodes. The reported incidence of metastases to the supraclavicular lymph nodes in patients with CAP is 0.28%.<sup>7</sup>

CAP is rarely diagnosed in men younger than 50 years. In this age group, the most common presentation is an asymptomatic patient with abnormal DRE or elevated PSA, or voiding difficulty. Other common presenting signs include bone pain, hematuria, perineal pain and urinary retention.<sup>10</sup>

Serum PSA and DRE are the most commonly used tools for prostatic cancer screening. They are relatively easy and noninvasive procedures to perform. The American Urological Association and the American Cancer Society recommend offering annual PSA testing and DRE from the age of 50 years to men with a normal risk of prostate cancer and from an earlier age to men at high risk.<sup>11</sup> In our case, if DRE had been included in the initial diagnostic process, there would have been no delay in diagnosis.

In the literature, metastatic CAP with LSCL as the first presentation has been reported rarely and only in patients over 45 years of age.<sup>1,2,7–9,12,13</sup> James et al<sup>12</sup> stated that metastatic CAP should be considered when metastatic adenocarcinoma is discovered in the left supraclavicular lymph nodes of men older than 45 years, and Kathleen et al<sup>9</sup> recommended that metastatic prostate carcinoma should be ruled out via immunoperoxidase staining for PSA in all men older than 45 years presenting with carcinoma of unknown primary origin in left-sided supra-diaphragmatic lymph nodes. Jones and Anthony<sup>1</sup> stated that a diagnosis of cervical adenocarcinoma of unknown primary origin should not be issued until prostatic origin has been ruled out. It is important to distinguish carcinoma of unknown primary origin from metastatic CAP, because of the wide difference in treatment and prognosis. Immunohistochemical staining for PSA could be helpful in determining a diagnosis of CAP,<sup>1,2,7–9</sup> but it is not absolutely specific. Some carcinoma of

salivary gland origin, female breast carcinoma and lung cancer can be positive for PSA stains.<sup>8,9</sup> Serum PSA level and prostate biopsy are indicated for establishing a definite diagnosis of CAP in patients with metastatic lesions of the neck positive for PSA staining.

The prognosis of metastatic CAP to the head and neck can be relatively good, with the possibility of prolonged survival after appropriate diagnosis and treatment.<sup>2,8,9,14</sup> Jones and Anthony<sup>1</sup> presented a series of 11 CAP patients with left-sided cervical lymph node metastases. Despite high-stage disease in these patients, six of 11 patients were alive and well 1–101 months after diagnosis (average 25.8 at publication). The five patients who died had an average survival of 34.4 months; the author stated that after appropriate treatment, their outcome was superior to those with metastatic adenocarcinoma of nonprostatic origin, who died at an average of 2 months from the time of diagnosis. Chitale et al<sup>12</sup> reported two patients with metastatic CAP and cervical lymphadenopathy; one has remained symptom-free for 3 years at publication, and the other has been symptom-free for 9 years. In Taiwan, Wang et al reported three CAPs (69, 73 and 79 years of age) presenting with LSCL and stated that hormone treatment has been shown to be of benefit even in patients in the advanced stages.<sup>14</sup>

In conclusion, male patients with persistent LSCL should have serum PSA level estimated at the time of initial presentation, even if they are less than 45 years of age. Subsequent immunohistochemical stains of their lymph node biopsies for PSA should also be performed. These are crucial to establishing a definitive diagnosis of CAP and, in turn, to instituting appropriate management and achieving the best possible outcome.

## References

1. Jones H, Anthony PP. Metastatic prostatic carcinoma presenting as left-sided cervical lymphadenopathy: a series of 11 cases. *Histopathology* 1992;**21**:149–54.
2. Copeland B, Clark JM, Sura A, Kilpatrick SE, Shockley W, Meredith S. Prostate carcinoma metastatic to the cervical lymph nodes: report of two cases and review of the literature. *Am J Otol* 2001;**22**:420–3.
3. Jemal A, Siegel R, Ward E, Hao Y, Xu J, Murray T, et al. Cancer statistics, 2008. *CA Cancer J Clin* 2008;**58**:71–96.
4. Department of Health, the Executive Yuan, Taiwan, R.O.C. *Cancer registry annual report 2007*. Taiwan.
5. Ries LAG, Eisner MP, Kosary CL, Hankey BF, Miller BA, Clegg L, et al. *SEER cancer statistics review, 1975–2001*. National Cancer Institute; 2004.
6. Lin DW, Porter M, Montgomery B. Treatment and survival outcomes in young men diagnosed with prostate cancer: a population-based cohort study. *Cancer* 2009;**115**:2863–71.
7. Hematpour K, Bennett CJ, Rogers D, Head CS. Supraclavicular lymph node: incidence of unsuspected metastatic prostate cancer. *Eur Arch Otorhinolaryngol* 2006;**263**:872–4.
8. Hunt JL, Tomaszewski JE, Montone KT. Prostatic adenocarcinoma metastatic to the head and neck and the workup of an unknown epithelioid neoplasm. *Head Neck* 2004;**26**:171–8.
9. Cho KR, Epstein JI. Metastatic prostatic carcinoma to supra-diaphragmatic lymph nodes: a clinicopathologic and immunohistochemical study. *Am J Surg Pathol* 1987;**11**:457–63.
10. Aprikian AG, Zhang ZF, Fair WR. Prostate adenocarcinoma in men younger than 50 years: a retrospective review of 151 patients. *Cancer* 1994;**74**:1768–77.

11. Andriole GL, Crawford ED, Grubb 3rd RL, Buys SS, Chia D, Church TR, et al. Mortality results from a randomized prostate-cancer screening trial. *N Engl J Med* 2009;**360**:1310–9.
12. Butler JJ, Howe CD, Johnson DE. Enlargement of the supraclavicular lymph nodes as the initial sign of prostatic carcinoma. *Cancer* 1971;**27**:1055–63.
13. Chitale SV, Harry L, Gaches CG, Ball RY. Presentation of prostatic adenocarcinoma with cervical lymphadenopathy: two case reports and review of the literature. *Otolaryngol Head Neck Surg* 2001;**125**:431–2.
14. Wang HJ, Chiang PH, Peng JP, Yu TJ. Presentation of prostate carcinoma with cervical lymphadenopathy: report of three cases. *Chang Gung Med J* 2004;**27**:840–4.