

Case Report

# Amyand's hernia with scrotal abscess presenting as acute scrotum

Yu-Hsiu Juan <sup>a</sup>, Kai-Hsiung Ko <sup>b</sup>, Yen-Lin Chen <sup>b</sup>, Chang-Hsien Liu <sup>b</sup>, Chih-Yung Yu <sup>b</sup>,  
Wei-Chou Chang <sup>b,\*</sup>, Guo-Shu Huang <sup>b</sup>

<sup>a</sup> Department of Radiology, Buddhist Hualien Tzu Chi General Hospital, Hualien, Taiwan, ROC

<sup>b</sup> Department of Radiology, Tri-Service General Hospital and National Defense Medical Center, Taipei, Taiwan, ROC

Received April 13, 2011; accepted August 19, 2011

## Abstract

Amyand's hernia is a rare form of inguinal hernia in which an inflamed appendix is incarcerated in a hernial sac. The clinical presentation of Amyand's hernia varies, depending on the extent of inflammation involved in the hernial sac and the presence or absence of a scrotal abscess. If a scrotal abscess is present, this usually indicates that the appendix in the hernial sac is perforated. However, without the availability of computed tomography (CT) scans, the condition is often preoperatively misdiagnosed as a strangulated inguinal hernia. We describe a rare case of a 64-year-old man who presented at our emergency room complaining of scrotal swelling and pain. Diagnosis of Amyand's hernia with a scrotal abscess was confirmed preoperatively by CT scan.

Copyright © 2012 Elsevier Taiwan LLC and the Chinese Medical Association. All rights reserved.

*Keywords:* acute scrotum; Amyand's hernia; computed tomography; inguinal hernia; scrotal abscess

## 1. Introduction

Claudius Amyand was a British surgeon who, in 1735, performed the first successful appendectomy from an inguinal hernia in which the inflamed appendix was contained in a right inguinal hernia in an 11-year-old boy.<sup>1</sup> The term Amyand's hernia was defined as an uncommon inguinal hernia that contains the appendix, which may be perforated, inflamed, or normal.<sup>2</sup> The presentation of an Amyand's hernia can vary, depending on its inflammatory extent, and closely resembles that of a strangulated inguinal hernia. The diagnosis is difficult to make preoperatively. If there is a scrotal abscess within the hernial sac, a perforated appendix is usually indicated. In a review of the literature, only Salemis et al<sup>1</sup> reported a case of Amyand's hernia complicated by a periappendicular abscess. However, a preoperative computed tomography (CT) scan was not performed, and the patient was misdiagnosed with a strangulated hernia.

\* Corresponding author. Dr. Wei-Chou Chang, Department of Radiology, Tri-Service General Hospital, 325, Section 2, Cheng-Kung Road, Neihu, Taipei 114, Taiwan, ROC.

E-mail address: [weichou.chang@gmail.com](mailto:weichou.chang@gmail.com) (W.-C. Chang).

Here we describe an unusual case presenting with symptoms and signs of acute scrotum whose final diagnosis was an Amyand's hernia with scrotal abscess, confirmed by an abdominal CT scan. To the best of our knowledge, this is the first case of Amyand's hernia with scrotal abscess presenting on reformatted CT images.

## 2. Case report

A 64-year-old man presented to our emergency department (ED) with a right scrotal enlargement. The patient reported sudden onset of pain in his right scrotum 3 hours before arrival. He stated that his right scrotum had become progressively swollen and tender. He had a history of left inguinal hernia repair 10 years previously and had a reducible right inguinal hernia for the previous 2 years. He stated that he had not experienced dysuria, hematuria, penile discharge, nausea, vomiting, or abdominal pain.

His vital signs at the ED were as follows: temperature, 37.2°C; pulse, 102 beats per minute, regular; and respiration, 20 breaths per minute. His blood pressure was 179/118 mmHg. An abdominal examination revealed normal

bowel sounds, but a bulging mass over his right inguinal region confluent with the superior aspect of the right scrotum was found. The right side of the scrotum was dramatically swollen and erythematous. Palpation elicited significant discomfort. The right-sided cremasteric reflex was absent. A plain radiograph image of the abdomen showed no signs of bowel obstruction.

Given the patient’s history of reducible right inguinal hernia and the physical examination findings, CT of the abdomen was performed. The abdominal CT images (Figs. 1 and 2) illustrated the path of the swollen appendix through the inguinal canal and into his right scrotum, along with appendiceal perforation and abscess formation. The abscess was confined within the hernial sac. A diagnosis of perforated appendicitis and a periappendicular abscess within a scrotal sac was confirmed.

The patient underwent an emergency appendectomy and herniorrhaphy using a modification of the Bassini method. No prosthetic mesh was used. The operative findings revealed a large inguinal hernia protruding into the right scrotum, with a suppurative perforated appendix and localized abscess formation within the sac, compatible with the CT imaging findings. Microscopically, infiltration of numerous lymphocytes and neutrophils in the submucosal and muscular layers of the appendix was observed, consistent with acute suppurative appendicitis (Fig. 3). The patient was discharged 6 days later in a stable condition.

3. Discussion

A noninflamed appendix within an inguinal hernia is uncommon, with the reported incidence varying from 0.28% to 1%.<sup>3</sup> The incidence of inguinal hernia containing an inflamed appendix is rare, estimated at 0.07–0.13%.<sup>4</sup> Amyand’s hernia usually occurs in the older population (>60 years), but a smaller number have presented in children.<sup>2</sup> Most cases occur on the right side, reflecting the usual intra-abdominal position of the organ and the fact that right-sided inguinal hernias are more common than left-sided hernias.<sup>5</sup> Although a handful of left-sided Amyand’s hernias have been reported, these may be associated with situs inversus, intestinal malrotation, or a mobile cecum.<sup>6</sup>

The most common presentation of Amyand’s hernia is a right inguinal mass that is inflamed and tender, with variable

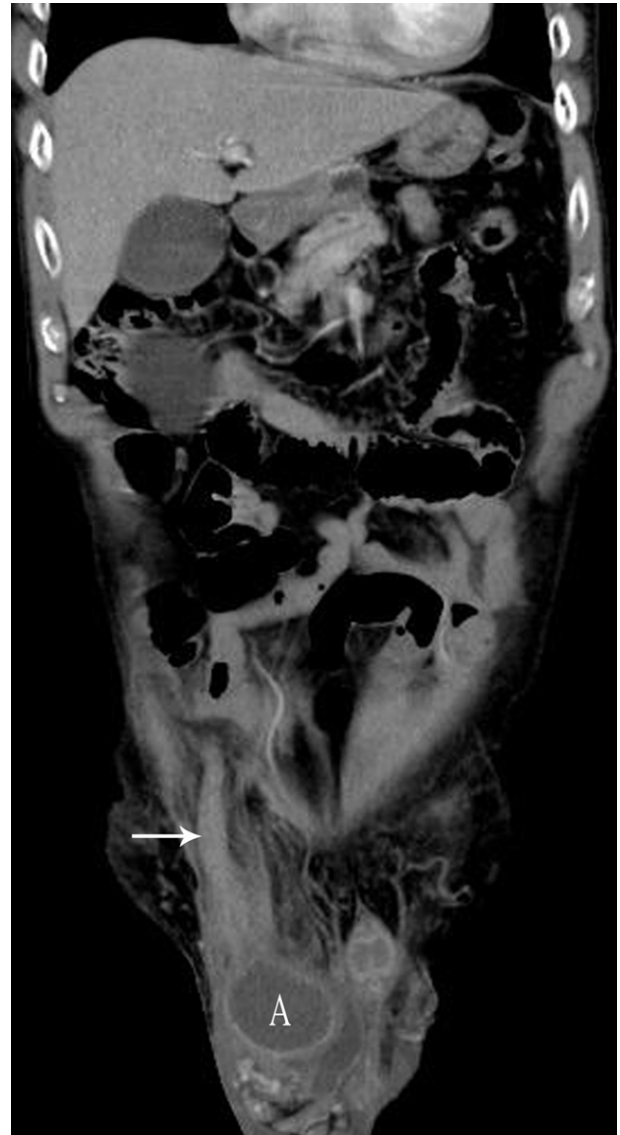

Fig. 2. Coronal reformat contrast-enhanced computed tomography image of the inguinal region showing the path of the swelling appendix (arrow) through the inguinal canal and into the right scrotum, along with perforation and abscess formation (denoted by A). The extent of septic changes was confined within the sac. The diagnosis of Amyand’s hernia with localized scrotal abscess was confirmed.

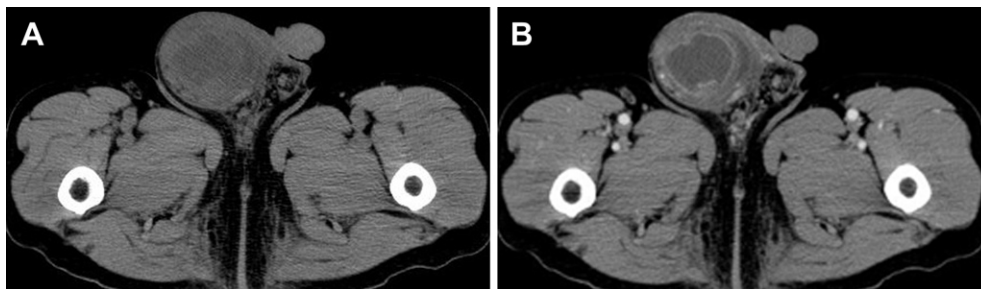


Fig. 1. (A) Noncontrast-enhanced and (B) contrast-enhanced axial computed tomography images of the inguinal region reveal marked enlargement of the right scrotum with wall thickening and edematous changes. There is localized fluid collection with rim enhancement within the right scrotum, compatible with an abscess. A small amount of perifocal hydrocele is also present.

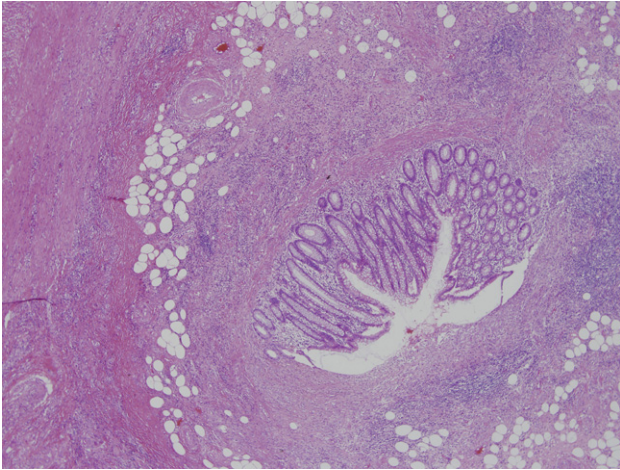


Fig. 3. Microscopic observation of infiltration of numerous lymphocytes and neutrophils in the submucosal and muscular layers of the appendix, consistent with acute suppurative appendicitis (hematoxylin and eosin staining; original magnification, 40 $\times$ ).

degrees of abdominal pain and vomiting. The classic signs of appendicitis, including a fever and leukocytosis, are often absent.<sup>2</sup> Preoperative diagnosis requires a high degree of clinical suspicion and awareness and is extremely difficult because the symptoms are nontypical and depend on the extent of periappendicular inflammation and the presence or absence of peritoneal contamination, and usually point to incarcerated or strangulated hernia.<sup>7</sup> In 2009 Coleman et al<sup>8</sup> reported a case of incarcerated appendicitis masquerading as epididymitis. The final diagnosis was revised as an Amyand's hernia after performance of an abdominal CT scan. Our case, presenting as acute scrotum in the ED, is a rare manifestation of an Amyand's hernia whose correct diagnosis was confirmed by an abdominal CT scan.

The list of diagnostic possibilities for a patient with an undifferentiated acute scrotum is extensive, including epididymitis, orchitis, Fournier's gangrene, hernia, testicular torsion, tumor, and scrotal skin infection. Amyand's hernia with a scrotal abscess should also be considered. Ultrasonography is the most useful diagnostic modality in the evaluation of scrotal complaints. However, in complicated cases, such as our particular case, ultrasonography has a limited role in the detection of the etiology, extent and surroundings. Therefore, a preoperative CT scan should be suggested when an acute scrotum is accompanied by a scrotal mass, sepsis, or bowel obstruction.

Fernando and Leelaratra<sup>9</sup> and Losanoff and Basson<sup>10</sup> defined Amyand's hernia as an inguinal hernia containing (1) a non-inflamed appendix, (2) an inflamed appendix, (3) a perforated appendix, or (4) acute appendicitis complicated with related or unrelated intra-abdominal pathology. The classification systems have been based on the surgical treatment recommended, which differs for each type of Amyand's hernia.

CT has been used in the preoperative evaluation of incarcerated inguinal hernias and was diagnostic of Amyand's hernia in many cases.<sup>1</sup> Luchs et al<sup>11</sup> were the first to describe cases (two) on CT scans. Constantine<sup>2</sup> illustrated four subtypes

of Amyand's hernia by abdominal CT images. He suggested that abdominal CT is particularly invaluable in the recognition of types 3 and 4, which are more complicated and diverse than types 1 and 2. The sagittal and coronal reformats are particularly useful in identifying the blind-ending tubular appendix arising from the cecum and entering the inguinal canal. This was exemplified in 2007 by Gillion et al<sup>12</sup> and Maizlin et al.<sup>13</sup>

Management of each type of Amyand's hernia is well established according to the intraoperative circumstances.<sup>10</sup> Type 1 hernias are treated using elective hernia repair, with or without appendectomy. The use of a prosthetic mesh can yield improved longevity of the repair. Surgical treatment for type 2 hernias is appendectomy and hernia repair, but mesh repairs are not recommended because of the increased risk of infection. A surgical approach for type 3 cases often relates to the extent of complications, which frequently require laparotomy. Thorough preoperative evaluation, including CT, of type 4 hernias can potentially detect the coexisting condition, avoid delay, help to plan the most appropriate procedure, and thus improve the outcome.<sup>2</sup> In our case, although a perforated appendix with abscess formation was found, the septic changes were well confined to the hernial sac. A preoperative CT confirmed this situation. Thus, our patient was treated according to type 2 recommendations and an uneventful outcome was obtained.

In conclusion, perforated Amyand's hernia with a scrotal abscess is an extremely rare condition and is often misdiagnosed as a strangulated inguinal hernia, which also represents a surgical emergency. Use of preoperative CT allows planning of proper surgical treatment to avoid complications and prevent sepsis.

## References

1. Salemis NS, Nisotakis K, Nazos K, Stavrinou P, Tsohataridis E. Perforated appendix and periappendicular abscess within an inguinal hernia. *Hernia* 2006;**10**:528–30.
2. Constantine S. Computed tomography appearances of Amyand hernia. *J Comput Assist Tomogr* 2009;**33**:359–62.
3. D'Alia C, Lo Schiavo MG, Tonante A, Taranto F, Gagliano E, Bonanno L, et al. Amyand's hernia: case report and review of the literature. *Hernia* 2003;**7**:89–91.
4. Sharma H, Gupta A, Shekhawat NS, Memon B, Memon MA. Amyand's hernia: a report of 18 consecutive patients over a 15-year period. *Hernia* 2007;**11**:31–5.
5. Pellegrino JM, Feldman SD. Case report: acute appendicitis in an inguinal hernia. *N J Med* 1992;**89**:225–6.
6. Johari HG, Paydar S, Davani SZ, Eskandari S, Johari MG. Left-sided Amyand hernia. *Ann Saudi Med* 2009;**29**:321–2.
7. House MG, Goldin SB, Chen H. Perforated Amyand's hernia. *South Med J* 2001;**94**:496–8.
8. Coleman K, Aurora T, Suri P, Hoffman RJ. Clinical confounder: an incarcerated appendix masquerading as epididymitis. *J Emerg Med* 2009 Jun 3.
9. Fernando J, Leelaratra S. Amyand's hernia. *Ceylon Med J* 2002;**47**:71.
10. Losanoff JE, Basson MD. Amyand hernia: a classification to improve management. *Hernia* 2008;**12**:325–6.
11. Luchs JS, Halpern D, Katz DS. Amyand's hernia: prospective CT diagnosis. *J Comput Assist Tomogr* 2000;**24**:884–6.
12. Gillion JF, Bornet G, Hamrouni A, Julles MC, Convard JP. Amyand and de Garengeot' hernias. *Hernia* 2007;**11**:289–90.
13. Maizlin ZV, Mason AC, Brown C, Brown JA. CT findings of normal and inflamed appendix in groin hernia. *Emerg Radiol* 2007;**14**:97–100.