



Case Report

Increased requirement for minute ventilation and negative arterial to end-tidal carbon dioxide gradient may indicate malignant hyperthermia

Ho-Tien Lin ^a, Shen-Chih Wang ^a, Zhiyi Zuo ^b, Mei-Yung Tsou ^a, Kwok-Hon Chan ^a,
Hui-Bih Yuan ^{a,*}

^a Department of Anesthesiology, Taipei Veterans General Hospital and National Yang-Ming University School of Medicine, Taipei, Taiwan, ROC

^b Department of Anesthesiology, University of Virginia Health System, Charlottesville, VA 22908-0710, USA

Received November 29, 2011; accepted July 6, 2012

Abstract

Characteristic signs of malignant hyperthermia (MH) include unexplained tachycardia, increased end-tidal carbon dioxide (EtCO₂) concentration, metabolic and respiratory acidosis, and an increase in body temperature above 38.8°C. We present the case of a patient with highly probable MH. In addition to sinus tachycardia and metabolic and respiratory acidosis, this patient also had a negative arterial to EtCO₂ gradient and an increased requirement for minute ventilation to maintain a normal EtCO₂ concentration, with signs of increased CO₂ production. Despite these signs of MH, the patient's rectal temperature monitoring equipment did not show an increase in temperature, although the temperature measured in the mouth was increased. This case illustrates the unreliability of measuring rectal temperature as a means of reflecting body temperature during MH and the usefulness of increased CO₂ production signs in helping to diagnose MH.

Copyright © 2014 Elsevier Taiwan LLC and the Chinese Medical Association. All rights reserved.

Keywords: blood gas analysis; body temperature; capnography; malignant hyperthermia; pulmonary ventilation

1. Introduction

A rapid increase in end-tidal carbon dioxide (EtCO₂) is one of the earliest signs of an episode of malignant hyperthermia (MH).¹ However, increased EtCO₂ may not present with an increased minute ventilation (MVe)^{2,3} or may be neglected due to normal arterial carbon dioxide concentrations (Paco₂).⁴ Under these circumstances, a negative gradient between Paco₂ and EtCO₂ [(a-Et)Pco₂], another early sign of MH, can be used as an additional diagnostic indication.⁴ We present here a clinically “almost certain” case of MH. An earlier diagnosis of MH could have been made if we had used an increased MVe and negative (a-Et)Pco₂ as signs of MH.

Conflicts of interest: The authors declare that there are no conflicts of interest related to the subject matter or materials discussed in this article.

* Corresponding author. Dr. Hui-Bih Yuan, Department of Anesthesiology, Taipei Veterans General Hospital, 201, Section 2, Shih-Pai Road, Taipei 112, Taiwan, ROC.

E-mail address: hbyuan@vghtpe.gov.tw (H.-B. Yuan).

2. Case report

A 71-year-old woman weighing 64 kg with a body mass index of 26 and of American Society of Anesthesiologists physical status II was scheduled for the excision of a thoracic spine T1–2 neurogenic tumor. The patient had no previous exposure to general anesthesia. There was no known family history of MH or myopathies. She had a history of asthma with no recent attack and drug treatment had been stopped 2 years previously. A preoperative pulmonary function test showed mild restrictive ventilatory impairment with a forced expiratory volume in the 1st second of expiration of 1.47 L (78% of predicted value).

Anesthesia was induced with fentanyl, propofol, and cis-atracurium. After uneventful endotracheal intubation, a radial arterial catheter, a central venous catheter via the internal jugular vein, and a rectal temperature probe were inserted. Anesthesia was maintained with isoflurane in an oxygen and air mixture. The patient's temperature was 36.0°C and her

EtCO₂ was 39 mmHg with an MVe of 4.3 L/minute immediately after induction (Fig. 1). The airway pressure was 24 cmH₂O and the dynamic respiratory compliance was 25.33 mL/cmH₂O.

The patient was placed in a prone position about 1 hour after the induction of anesthesia. After the change to a prone position, her airway pressure increased and the ventilator was switched to pressure control mode, with the inspiratory pressure set at 24 cmH₂O; respiratory compliance dropped to 20.48 mL/cmH₂O. During the next hour, MVe was gradually increased from 4.7 L/minute to 8.0 L/minute by increasing the inspiratory pressure setting to 28 cmH₂O and increasing the respiratory rate to 14 per minute to keep the EtCO₂ around 40 mmHg. The patient's respiratory compliance was 22.80 mL/cmH₂O and her temperature remained at 36.1°C during this period.

In the next 30 minutes, the EtCO₂ gradually increased to 47 mmHg with an increase in heart rate to 100 beats per minute (bpm) and decreased blood pressure (systolic blood pressure around 90 mmHg). At this time, the patient's temperature was 36.5°C. There was an estimated concurrent blood loss of 1200 mL. Colloid and blood products were used for replacement. Arterial blood gas (ABG) analysis showed metabolic acidosis (base excess, BE = -10 mmol/L) with a pH of 7.27, Paco₂ 37.7 mmHg, and a negative (a-ET)Pco₂ gradient (Table 1; Fig. 1). Sodium bicarbonate was given to correct acidosis. Over the next 20 minutes the EtCO₂ continued to increase to 57 mmHg. MH was highly suspected, although the rectal temperature was only 36.8°C. Subsequent ABG analysis showed a more significant negative (a-ET)Pco₂ gradient, with pH 7.24, Paco₂ 44.7 mmHg, and BE -8 mmol/L (Table 1). We checked whether the temperature probe was in the correct position. The gas analysis machine, CO₂ absorber,

Table 1

Sequential data at different time points for this patient.

	Time after induction of anesthesia (min)					
	70	160	180	210	240	290
pH	7.381	7.266	7.240	7.108	7.004	7.467
Paco ₂ (mmHg)	36.4	37.7	44.7	75.3	107.7	33.5
Etco ₂ (mmHg)	33	47	57	92	99 ^a	NA
(a-Et)Pco ₂ (mmHg)	3.4	-9.3	-12.3	-16.7	NA	NA
K ⁺ (mmol/L)	3.43	4.19	3.93	3.93	4.92	5.0
Temperature ^b (°C)	36.0	36.5	36.8	36.8	37.2, ^b 38.4 ^c	37.1 ^d
MVe (L/min)	5.3	8.0	8.0	8.0	10.0	9.0

(a-Et)Pco₂ = gradient between Paco₂ and end-tidal CO₂; Etco₂ = end-tidal CO₂; MVe = minute ventilation; NA = not applicable; Paco₂ = arterial carbon dioxide concentrations.

^a Upper measurement range of capnography.

^b Rectal temperature.

^c Oral temperature.

^d Tympanic membrane temperature.

and breathing circuit were checked to exclude equipment error. During the checking, the breathing circuit was found to be very warm and humid and the EtCO₂ was increased rapidly to 92 mmHg. The ABG results were pH 7.108 and Paco₂ 75.3 mmHg (Table 1; Fig. 1). Her heart rate was 130 bpm. The diagnosis of MH was made and treatment commenced immediately. At this time, the patient's rectal temperature still showed 36.8°C despite correct positioning having been confirmed.

Isflurane was withdrawn immediately. Anesthesia was maintained with propofol infusion. The anesthetic machine was replaced and the patient's lungs were hyperventilated with 100% O₂. Rapid infusion of dantrolene was started at a dose of 2 mg/kg. The operation ended 30 minutes later and the patient was returned to a supine position. Her oral temperature was 38.4°C, whereas the rectal temperature equipment still read 37.2°C. Her heart rate decreased progressively from 145 bpm to 115 bpm after the dantrolene infusion. Nevertheless, the EtCO₂ was more than 99 mmHg (the upper measurement limit of the capnograph), with blood gas analysis showing pH 7.004 and Paco₂ 107.7 mmHg (Table 1; Fig. 1). The patient was admitted to the intensive care unit (ICU) under stable hemodynamic conditions.

On arrival in the ICU, the patient's tympanic temperature was 39.0°C. Ice water irrigation via a nasogastric tube and an alcohol bath were used to cool the patient. Her temperature and Paco₂ shortly returned to normal. ABG analysis showed pH 7.467, Paco₂ 33.5 mmHg, BE 0.3 mmol/L and K⁺ 5.0 mmol/L. Her tympanic temperature was 37.1°C 45 minutes after being admitted to the ICU. Her creatinine kinase peaked at 107 U/L during the morning of the 1st postoperative day. The patient was extubated on the 1st postoperative day and was closely monitored for another 24 hours. There was no further sign of MH and no additional dantrolene was given in the ICU. The patient was discharged from hospital 6 days later with an uneventful postoperative course. The patient and her family had been informed of possible MH during anesthesia and surgery, but she had not undergone a muscle biopsy test. According to the clinical grading scale of MH, the patient's

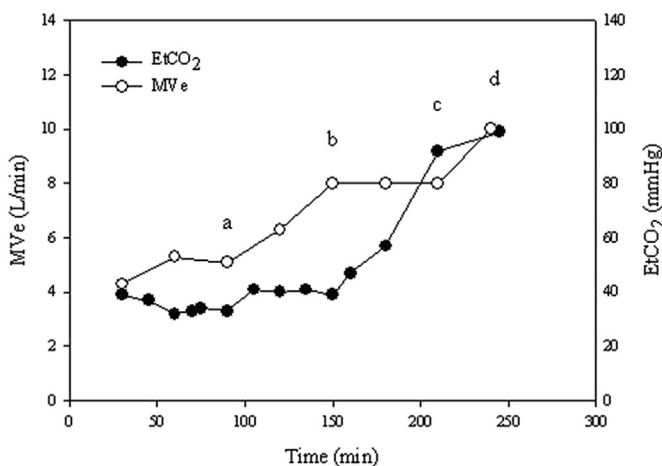


Fig. 1. Minute ventilation and end-tidal CO₂ (EtCO₂) versus time. Time starts at induction of anesthesia. The patient was relatively stable for about 80 minutes, but minute ventilation (MVe) was gradually increased to maintain EtCO₂ (point a to b). Increasing EtCO₂ was then noted in spite of the increased MVe (8.0 L/minute), whereas the arterial CO₂ concentration remained normal (point b). EtCO₂ increased rapidly later, and malignant hyperthermia was diagnosed (point c). Dantrolene was infused and the patient remained hemodynamically stable, whereas EtCO₂ stayed at the high extreme (point d).

score was 58, which places her in the highest probability category of “almost certain”.⁵

3. Discussion

This case illustrates several interesting points. Firstly, an initial increase in EtCO_2 can be masked by increased MVE. Secondly, negative (a-Et) PCO_2 can be present in spite of a relatively normal Paco_2 . Thirdly, rectal temperature monitoring may not be a reliable method of detecting changes in body temperature during MH. In this patient, increased EtCO_2 was seen early during anesthesia. However, definite treatment was not given immediately due to the relatively normal Paco_2 , concern about possible equipment error, and inaccurate body temperature measurement. Under such circumstances, the measurement of body temperature at a different site and a negative (a-Et) PCO_2 or venous blood gas analysis of PCO_2 , or both, should be useful in making an early diagnosis.

An increase in EtCO_2 is one of the earliest signs of MH. Although continuous capnographic monitoring is cited as a means of detecting this sign of an MH episode, increased MVE can confound the interpretation of the capnographic data. Increased MVE can initially normalize the increased EtCO_2 . This process can confuse the clinical picture and may delay the diagnosis of MH. This situation is especially difficult to recognize during laparoscopic procedures.^{2,3} In our patient, the gradual adjustments of MVE to maintain normocarbina in the early period (Fig. 1) might have helped to mask increasing CO_2 production and delayed the diagnosis of MH. Although the increased physiological dead space could also explain increased MVE, the possibility was excluded due to there being no significant change in lung compliance during this period. This case illustrates the necessity for EtCO_2 to always be evaluated in conjunction with MVE. When the MVE requirement exceeds the predicted MVE requirement, further investigation is necessary, even when the capnographic data are within the normal range. If all other sources of increased MVE requirement are excluded, an increased central venous CO_2 to Paco_2 gradient may help to indicate the diagnosis of MH.^{6,7}

Kwetny and Finucane⁴ first described the phenomenon of negative (a-Et) PCO_2 gradient during an episode of MH. Negative (a-Et) PCO_2 values were first observed during anesthesia more than 50 years ago by Nunn and Hill.⁸ Thereafter, this phenomenon was noticed in pregnant women, infants, and small children during anesthesia.^{9,10} Factors such as increased cardiac output and CO_2 production, low total lung compliance, and reduced functional residual capacity are responsible for this phenomenon.¹¹ Patients with an MH episode have increased cardiac output and CO_2 production. The PCO_2 of most alveolar gas is less than Paco_2 , but in the terminal part of the expirate, the alveolar PCO_2 may increase rapidly toward mixed venous PCO_2 and exceeds Paco_2 in the presence of MH because a large amount of CO_2 is discharged into the lungs. Increased cardiac output and pulmonary blood flow result in better perfusion of the alveoli and facilitate the increase in EtCO_2 . Thus the capnogram's Phase III slope increases, and this part of the PCO_2 concentration is more likely to be

sampling venous CO_2 (PvCO_2) rather than Paco_2 .¹¹ Therefore a negative (a-Et) PCO_2 can be an early sign of MH and be used as a diagnostic and monitoring parameter during MH crisis.⁴ During the MH episode in our patient, the negative (a-Et) PCO_2 gradient (-9.3 mmHg) first appeared 160 minutes after the induction of anesthesia (Table 1). Although other factors, such as obesity (body mass index 26), a history of asthma with impaired lung function, and prone position might have contributed to the negative (a-Et) PCO_2 gradient in our patient, the venous CO_2 concentration should be checked to confirm the increase in CO_2 production. Unfortunately, we did not perform this examination. Based on this case, it is reasonable to suggest that parameters such as (a-Et) PCO_2 , central venous CO_2 saturation (Scv CO_2), and mixed venous CO_2 saturation (Sv CO_2) that are heavily affected by CO_2 production should be more sensitive to the early detection of MH than those that can also be influenced by CO_2 elimination, i.e., EtCO_2 and Paco_2 .

Hyperthermia is a later sign of MH and is typically absent when the diagnosis is initially suspected. However, hyperthermia can also be missed with certain monitoring methods. Core temperature measured at the pulmonary artery, distal esophagus, tympanic membrane, or nasopharynx is a reliable monitor when body temperature increases during MH. Some of these measurements are invasive and may not be practical in many instances.^{12,13} However, core temperature can be estimated with reasonable accuracy using oral, axillary, bladder, and rectal temperatures, except during extreme thermal perturbations.^{12,13} Skin surface and rectal temperatures are usually well correlated with core temperature, but may not increase appropriately during MH crises.¹⁴ Bladder temperature is equal to rectal temperature when the urine flow is low, but is equal to the pulmonary artery temperature when the flow is high.¹⁵ In our patient, the rectal temperature was measured due to its accessibility during neurosurgery. It peaked at 37.2°C prior to when the patient was sent to the ICU. The tympanic membrane temperature measured on arrival in the ICU was 39.0°C . We used a Philips-Agilent temperature monitor (Germany), which was maintained and checked for accuracy by a Philips-qualified engineer every 3 months. No report of rectal temperature monitor malfunction was noted. The inaccuracy of using rectal temperature as an estimate of core temperature during an episode of MH in our patient might be due to fecal insulation or relatively low perfusion of the rectum during anesthesia.¹⁶ Thus we suggest that rectal temperature should be interpreted carefully and other temperature monitoring methods should be sought during such episodes.

In conclusion, increased EtCO_2 is an early sign of MH crisis, but can often be masked by hyperventilation. Careful evaluation of capnographic data in conjunction with MVE throughout the course of the crisis is extremely important. Negative arterial to EtCO_2 gradient can be an early sign of MH, even when Paco_2 is normal. An increased MVE in combination with negative (a-Et) CO_2 gradient may increase awareness of MH during anesthesia and help in the earlier diagnosis of such crisis.

Acknowledgments

This work is attributed to the Department of Anesthesiology, Taipei Veterans General Hospital and National Yang-Ming University, Taiwan, R.O.C. Financial support was obtained solely from departmental sources.

References

1. Triner L, Sherman J. Potential value of expiratory carbon dioxide measurement in patients considered to be susceptible to malignant hyperthermia [letter]. *Anesthesiology* 1981;**55**:482.
2. O'Neill SS, Smurthwaite GJ. Malignant hyperthermia presenting during laparoscopic adrenalectomy. *Anaesthesia* 2008;**63**:540–3.
3. Karan SM, Crowl F, Muldoon SM. Malignant hyperthermia masked by capnographic monitoring. *Anesth Analg* 1994;**78**:590–2.
4. Kwetny I, Finucane BT. Negative arterial to end-tidal carbon dioxide gradient: an additional sign of malignant hyperthermia during desflurane anesthesia. *Anesth Analg* 2006;**102**:815–7.
5. Larach MG, Localio AR, Allen GC. A clinical grading scale to predict malignant hyperthermia susceptibility. *Anesthesiology* 1994;**80**:771–9.
6. Gronert GA, Theye RA. Halothane-induced porcine malignant hyperthermia: metabolic and hemodynamic changes. *Anesthesiology* 1976;**44**:36–43.
7. Gronert GA, Ahern CP, Milde JH. Treatment of porcine malignant hyperthermia: lactate gradient from muscle to blood. *Can Anaesth Soc J* 1986;**33**:729–36.
8. Nunn JF, Hill DW. Respiratory dead space and arterial to end-tidal carbon dioxide tension difference in anaesthetized man. *J Appl Physiol* 1960;**15**:383–9.
9. Shankar KB, Moseley H, Kumar Y. Negative arterial to end-tidal gradients. *Can J Anaesth* 1991;**38**:260–1.
10. Shankar KB, Moseley H, Kumar Y, Vemula V. Arterial to end-tidal carbon dioxide tension difference during caesarean section anaesthesia. *Anaesthesia* 1986;**41**:698–702.
11. Bhavani-Shankar K, Moseley H, Kumar AY, Delph Y. Capnometry and anaesthesia. *Can J Anaesth* 1992;**39**:617–32.
12. Bissonnette B, Sessler DI, LaFlamme P. Intraoperative temperature monitoring sites in infants and children and the effect of inspired gas warming on esophageal temperature. *Anesth Analg* 1989;**69**:192–6.
13. Cork RC, Vaughan RW, Humphrey LS. Precision and accuracy of intraoperative temperature monitoring. *Anesth Analg* 1983;**62**:211–4.
14. Iaizzo PA, Kehler CH, Zink RS, Belani KG, Sessler DI. Thermal response in acute porcine malignant hyperthermia. *Anesth Analg* 1996;**82**:782–9.
15. Horrow JC, Rosenberg H. Does urinary catheter temperature reflect core temperature during cardiac surgery? *Anesthesiology* 1988;**69**:986–9.
16. Stopfkuchen-Evans M, Farber ES, Vacanti FX. Thermoregulation and temperature monitoring. In: Vacanti CA, Sikka PK, Urman RD, Dershwitz M, Segal BS, editors. *Essential clinical anesthesia*. 1st ed. New York: Cambridge University Press; 2011. pp. 198–202.