



Original Article

# Endoscopic hematoma evacuation in patients with spontaneous supratentorial intracerebral hemorrhage

Wei-Hsin Wang<sup>a,b</sup>, Yi-Chieh Hung<sup>a</sup>, Sanford P.C. Hsu<sup>a,b</sup>, Chun-Fu Lin<sup>a,b</sup>, Hsin-Hung Chen<sup>a,b</sup>, Yang-Hsin Shih<sup>a,b</sup>, Cheng-Chia Lee<sup>a,b,c,\*</sup>

<sup>a</sup> Department of Neurosurgery, Neurological Institute, Taipei Veterans General Hospital, Taipei, Taiwan, ROC

<sup>b</sup> National Yang-Ming University School of Medicine, Taipei, Taiwan, ROC

<sup>c</sup> Department of Neurosurgery, Hsinchu Branch, Taipei Veterans General Hospital, Hsinchu, Taiwan, ROC

Received October 4, 2013; accepted August 13, 2014

## Abstract

**Background:** Surgical evacuation of spontaneous supratentorial intracerebral hemorrhage (ICH) is controversial because the traditional surgical approach sometimes causes further brain injury. The introduction of the neuroendoscope has brought with it the new idea of minimal invasiveness, which may improve the surgical results of ICH.

**Methods:** Twenty-one patients with spontaneous supratentorial ICH underwent endoscopic hematoma evacuation between December 2010 and January 2012. Safe entry points could be Kocher's, Keen's, or Frazier's point, depending on the locations of the hemorrhages. The surgical steps were as follows: (1) cortical incision and dilation of the channel; (2) introduction of the transparent sheath; (3) gushing out of the hematoma under high intracranial pressure; (4) changing the angle of the transparent sheath, endoscope, and suction tip to remove residual hematoma; and (5) paving a layer of hemostatic agents after hematoma removal.

**Results:** The median operative time was 120 minutes (range: 90–190 minutes), and the median blood loss was 160 mL (range: 50–300 mL). The median duration of intensive care unit stay was 6 days (range: 2–18 days). The median hematoma evacuation ratio was 90% (range: 60–99%). Two patients had rebleeding events, and the mortality rate was 9.5% ( $n = 2/21$ ). The median Glasgow Coma Scale score improved from 8 to 11 within 1 week after surgery, and the median Glasgow Outcome Scale score was 3 after 6 months and 12 months follow-up.

**Conclusion:** With the introduction of the minimally invasive techniques and the evolution of the neuroendoscope and hemostatic agents, the median operative time and blood loss have been significantly decreased. Although the hematoma evacuation rates were similar between the endoscope (90%) and craniotomy (85%) groups, the median intensive care unit stay was decreased from 11 days to 6 days due to reduced surgical invasiveness. This represents an important advancement in treating spontaneous supratentorial ICH, and provides a measured preview of the promising results that can be expected in the future.

Copyright © 2014 Elsevier Taiwan LLC and the Chinese Medical Association. All rights reserved.

**Keywords:** Glasgow coma scale; Glasgow outcome scale; Neuroendoscopy; spontaneous intracerebral hemorrhage; surgical evacuation

Conflicts of interest: The authors declare that there are no conflicts of interest related to the subject matter or materials discussed in this article.

\* Corresponding author. Dr. Cheng-Chia Lee, Department of Neurosurgery, Neurological Institute, Taipei Veterans General Hospital, 201, Section 2, Shih-Pai Road, Taipei 112, Taiwan, ROC.

E-mail addresses: [cclee12@vghtpe.gov.tw](mailto:cclee12@vghtpe.gov.tw), [yfnaughty@gmail.com](mailto:yfnaughty@gmail.com) (C.-C. Lee).

## 1. Introduction

Spontaneous supratentorial intracerebral hemorrhage (ICH) affects ~20 in 100,000 people annually and the mortality is >40%.<sup>1</sup> For the most part, survivors are left handicapped. Although the clinical outcome is mainly determined by the patient's initial presentation, early surgical intervention is crucial and urgent in selected patients. In the previous

literature, patients with hematomas  $\leq 1$  cm from the cortical surface were more likely to have a favorable outcome from early surgery than those with deep hematomas.<sup>2</sup> However, with the evolution of the neuroendoscope and hemostatic agents, the surgical evacuation of ICH in deep location is now safer and less invasive than before. Here, we present our series of patients with spontaneous supratentorial ICH who underwent endoscopic hematoma evacuation. The surgical indication, timing, surgical technique, and long-term results are discussed.

## 2. Methods

### 2.1. Patient population

A consecutive series of 21 patients with spontaneous supratentorial ICH underwent endoscopic hematoma evacuation between December 2010 and January 2012. Without randomizing the grouping, another 24 patients with spontaneous supratentorial ICH underwent hematoma evacuation by craniotomy were also included for comparison. These patients' general data, and their symptoms and signs were retrospectively collected. Patients and their families who enrolled in this study were informed retrospectively, and all of them agreed to the use of clinical parameters via a process of de-identification. All patients underwent brain computed tomography (CT) to localize the ICH. CT angiography or a contrast CT checkup was used for some patients with ICH in unusual locations to exclude the possibility of abnormal arteriovenous malformations, fistulas, aneurysms, or other vascular lesions. Coagulation functions including bleeding time, prothrombin time, activated partial thromboplastin time, and platelet count were also evaluated to avoid intraoperative bleeding. Other coagulation tests including protein C, protein S, fibrinogen, platelet function, D-dimer, and antiphospholipid antibodies are used on a case-by-case basis. In an earlier case, a thin-cut CT scan was arranged for intraoperative navigation.

The inclusion criteria were consciousness disturbance with one of the following: (1) a putamen ICH with hematoma volume  $> 30$  mL; or (2) subcortical hemorrhage  $> 30$  mL with a significant mass effect (midline shift  $> 5$  mm and sulcus effacement). The exclusion criteria were tumor, trauma, vascular lesions, or other intracranial lesions. End-stage renal disease or Child Class C liver cirrhosis was not a contraindication for surgical evacuation. However, a neurosurgeon had requested that the coagulopathy status be corrected before the operation. According to the basic coagulation tests, the patients who had low platelet counts proceeded with platelet infusion, and FFP (Fresh Frozen Plasma) and vitamin K were prescribed to patients who had abnormal international normalized ratio. For patients with antiplatelet medications (e.g., aspirin or clopidogrel), platelet infusion was necessary even though the patients had normal platelet counts, prothrombin time, and activated partial thromboplastin time. If the coagulopathy of the patients could not be corrected, we explained the surgical risks to the family and treated the patients conservatively.

### 2.2. Entry point selection and patient preparation

The entry point was determined by the location of the hemorrhage. The entry point could be Kocher's point (Fig. 1A), Keen's point (Fig. 1B), or Frazier's point (Fig. 1C); similar to the entry points of ventriculostomy. The only difference was the trajectory. If the patient had putamen ICH, the Kocher's point was the best point of entry, and the trajectory was lateral to that of ventriculostomy. If the patient had thalamic ICH with temporal expansion, the Keen's point location of entry might have been the best choice. Frazier's point was suitable for occipital extension of the ICH. To monitor intracranial pressure (ICP), contralateral ventriculostomy for ventricular catheter placement was performed in all patients with ICH. Mayfield head fixation for navigation was used in some of our cases, but it was not necessary for all patients. For patients who had ICH in a superficial location, or who had larger ICH for puncture, it was not necessary to fix their heads. The monitor and the holder of the endoscope were placed on the opposite side of the patient's chest.

### 2.3. Endoscopic hematoma evacuation

After undergoing anesthesia, the patient was put in the supine or prone position, and a linear scalp incision ( $\sim 5$  cm) was then made. A 2.5–3-cm burr hole was created. After tenting the dura, it was opened in a U shape. A 1-cm cortical incision with bipolar cauterization was made, and the ventricular catheter with a sutured glove (Fig. 2B) was inserted. The glove was ballooned, and the entry tract was created. A transparent plastic sheath (ViewSite Brain Access System, Vycor Medical Inc., Bohemia, NY, USA) was then placed (Fig. 2D). After establishing a channel, the endoscope was introduced by hand into the space that was created by the hematoma. Most hematomas may gush out due to high pressure, so we applied a 37-mm  $0^\circ$  rod-lens endoscope (18 cm in length: KARL STORZ GmbH & Co. KG – Tuttlingen, Germany) to aspirate the residual hematoma.

There are three methods to aspirate a hematoma in an extreme angle corner: (1)  $30^\circ$  and  $45^\circ$  rod-lens endoscope (Fig. 2A); (2) angled suction (either anterior or posterior angled suction with a 5-mm, 7-mm, or 10-mm diameter, Fig. 2C); and (3) rotation manipulation of the sheath within the brain parenchyma. The transparent sheath provides excellent visualization: the deepest part of the hematoma should be removed first, and the sheath withdrawn gradually, facilitating the pushing of the residual part of the hematoma into the tip of the sheath. Most of the time, the surgeon can hold the endoscope in one hand, and aspirate the hematoma by smooth-tip suction with the other hand. In addition, a suction adaptor can be used for rapid adjustment of suction power (Fig. 2E). If there is only oozing without active bleeders, the oozing can be stopped with hemostatic agents. If an active bleeder needs cauterization, the surgeon may use bipolar forceps with the endoscope held by an assistant or holder. In our experience, hemostasis in typical hypertensive ICH can be achieved by hemostatic agents (such as FloSeal Hemostatic

**A** Rt Koch's point

54 y/o male  
Left putamen ICH  
GCS: E3V4M5

**B** Rt Keen's point

85 y/o male  
Right subcortical ICH  
GCS: E3V4M5

**C** Rt Frazier's point

65 y/o female  
Right occipital ICH  
GCS: E1V1M4

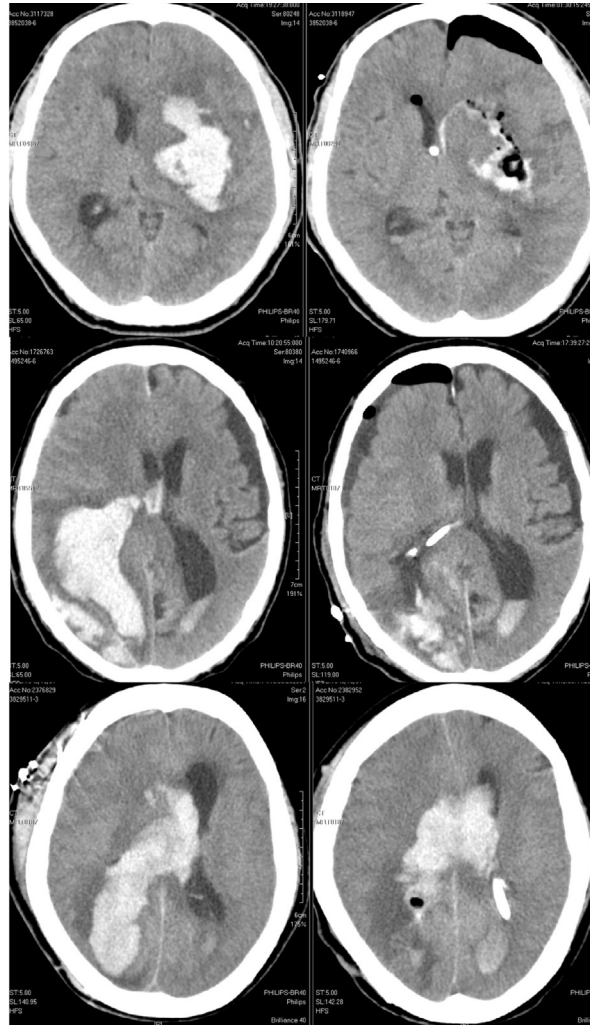

Fig. 1. The illustrated case underwent endoscopic hematoma evacuation via (A) right Koch's point. There was minimal brain injury after operation and the hematoma evacuation rate was >95%. Postoperative GOS: 4. (B) Right Keen's point. Extraventricular drainage was also done for intraventricular hemorrhage drainage and ICP monitoring. Hematoma evacuation rate was >95%. Postoperative GOS: 4. (C) Right Frazier's point. Extraventricular drainage was also done for intra-ventricular hemorrhage drainage and ICP monitoring. Hematoma evacuation rate was around 60%. Postoperative GOS: 3. GOS = Glasgow Outcomes Scale; ICP = intracranial pressure.

Matrix or ground Surgicel, absorbable hemostat). However, excess cauterization is not necessary and may cause neural damage. The most important steps of the entire procedure are illustrated in Fig. 3. Operative time and blood loss were also recorded for data completion.

#### 2.4. Postoperative care and radiological follow-up

Postoperative systolic blood pressure must be strictly controlled at <160 mmHg, and the presence of excessive fluid is not allowed. ICP was measured through the ventricular catheter, and kept below 20 mmH<sub>2</sub>O. Immediately after stabilizing the patient, brain CT scan was arranged for all patients undergoing hematoma evacuation. Hematoma volumes were calculated from the sum of the areas contoured on each slice, multiplied by the slice thickness (usually 5 mm). Based upon the experience of tumor volume calculation from radiosurgery, the trapezoidal rule formula demonstrated that with accurate delineation on at least five slices, the calculated volume had an

expected error rate of  $\leq 10\%$ . Therefore, this kind of measurement generally has an uncertainty of 10% for tomographic imaging utilized for a structural target such as a hematoma.<sup>3</sup> The hematoma evacuation rate was calculated and presented by percentage as:

$$\frac{\text{preoperative hematoma volume} - \text{postoperative hematoma volume}}{\text{preoperative hematoma volume}}$$

Any morbidity and mortality were recorded, and the Glasgow outcome scale (GOS) score was recorded at 6 months and 1 year after operation.

#### 2.5. Statistical analysis

Descriptive statistics for all data are presented as the median and range for continuous variables and as frequency and percentages for categorical variables. For categorical variables, cross-tables were generated, and Fisher's exact,

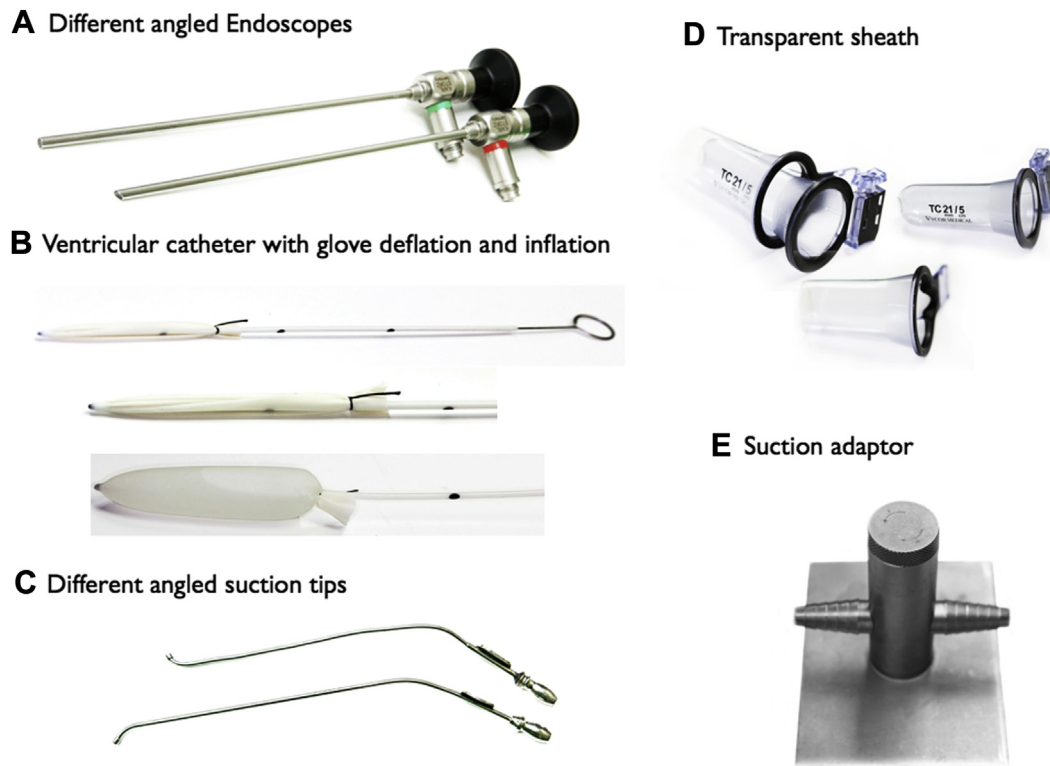


Fig. 2. The equipment needed for endoscopic intracerebral hematoma evacuation. (A) Endoscope with different angles of 0°, 30°, and 45°. (B) Hand-made ventricular catheter with a glove as a channel dilator: deflation and inflation in close look. (C) Different-angled suction tips: pointing to up, pointing to down, and different sizes (5 mm, 7 mm, and 10 mm in diameter). (D) Transparent sheath, with styilet. (E) Suction adaptor.

Pearson's  $\chi^2$ , or Mantel–Haenszel tests were used to compare distributions. For continuous variables with or without equal variances, independent *t* tests were used to investigate differences between subsets of patients classified by categorical data. Statistical significance was a  $p < 0.05$ . All analyses were completed using commercial statistical software (version 20.0; SPSS, IBM corporation, United States).

### 3. Results

The median age of the 21 patients who underwent endoscopic hematoma evacuation was 57.3 years (range: 36–85 years). As for the location of the hematomas in the 21 ICH cases, there were 16 (76%) in the putamen and five (24%) in the subcortical area. Nineteen patients (90%) underwent surgery within 6 hours (median: 3 hours) since the time of the first brain CT (Table 1).

The median operation time was 120 minutes (range: 90–190 minutes), and the median blood loss during the operation was 160 mL (range: 50–300 mL). The median evacuation rate was 90% (range: 60–99%). The median time of intensive care unit (ICU) stay was 6 days (range: 2–18 days). Extraventricular drainage was performed for ICP monitoring and to ensure adequate cerebrospinal fluid drainage in each patient. Only five patients needed a permanent ventriculoperitoneal shunt. In general, there was no difficulty entering the clot, either by using the navigation system or just by planning the trajectory according to

the preoperative images. In comparison with the other patient group that underwent craniotomy for spontaneous supratentorial ICH, the significant differences were: median operation time (120 minutes vs. 230 minutes,  $p = 0.009$ ), intraoperative blood loss (160 mL vs. 530 mL,  $p < 0.001$ ), and ICU stay (6 days vs. 11 days,  $p = 0.017$ ) (Table 2).

Regarding prognosis, two patients had rebleeding on Postoperative Day 3 and Day 7, respectively. Rebleeding in the original location was seen in one patient (on Postoperative Day 3), and in a remote location (midbrain ICH) in another patient (on Postoperative Day 7). The mortality rate was 9.5% (2 of 21 patients); one patient died from massive midbrain bleeding and one died because of severe pneumonia. The median preoperative Glasgow Coma Scale (GCS) score was 8 and the median GCS score 1 week after surgery was 11. The level of recovery was evaluated 6 months and 1 year after surgery and the median GOS scores were both 3. In comparing the other patient group that underwent craniotomy for spontaneous supratentorial ICH, there were no significant differences in any aspect of the patients' complications and outcome (Table 2).

If the spontaneous supratentorial ICHs were divided into two groups by location, there would be no significant differences between the two groups, the hematoma evacuation rate, GCS improvement, or GOS score. The two rebleeding events and mortalities involved patients with putaminal ICH (Table 3).

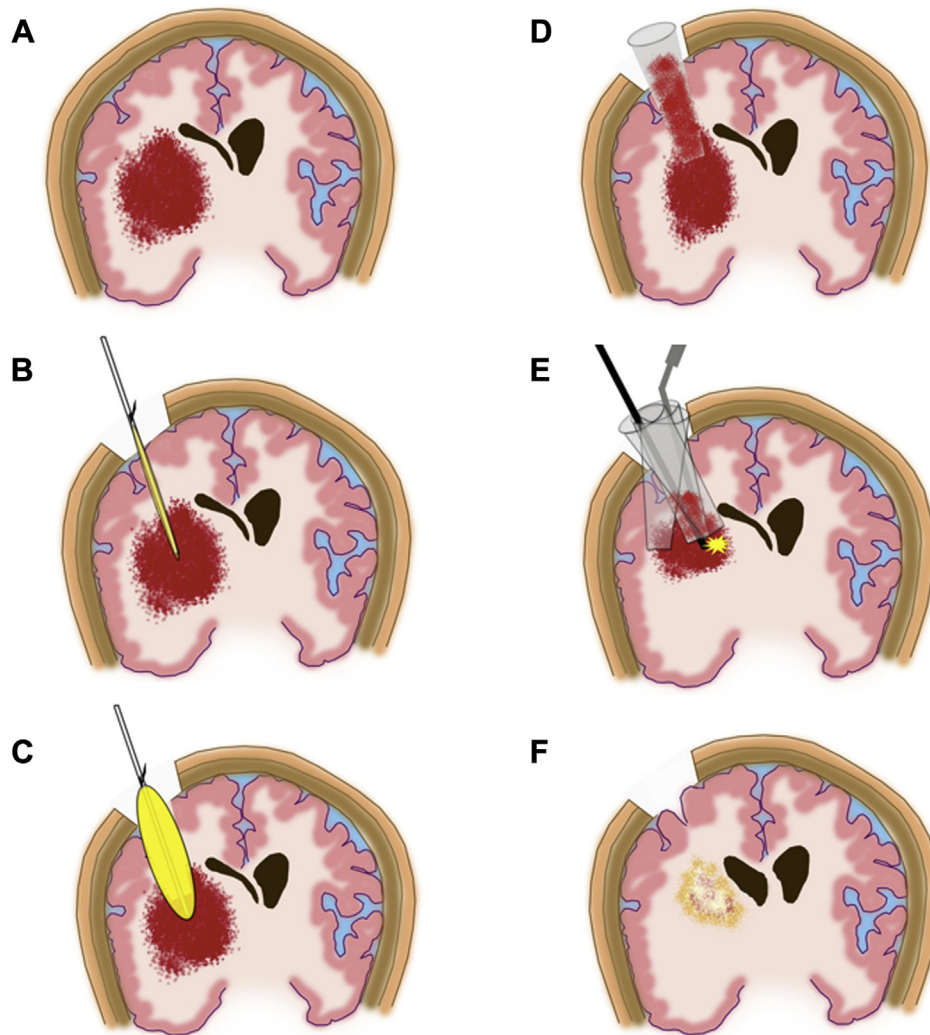


Fig. 3. Cartoon picture diagram of the strategy for endoscopic hematoma evacuation. (A) Intracerebral hematoma usually has a mass effect and causes midline shift. (B) Incise the cortex and insert the ventricular catheter with sutured glove. (C) Dilate the working channel by ballooning the groove. (D) Introduce the transparent sheath and begin central decompression. Hematoma will gush out under higher intracranial pressure. (E) Change the angle of transparent sheath, and use different angles of endoscope and angles of suction tips to remove residual hematoma. As the sheath is withdrawn, the cavity created by the hematoma will collapse. The resting hematoma will be pushed to within view of the sheath. (F) A layer of hemostatic agents is paved for hemostasis.

#### 4. Discussion

Brain injury after ICH is related to mechanical compression and the toxic effect of the blood clot.<sup>4,5</sup> Early surgery to limit the mechanical compression of normal brain tissue and the toxic effects of hematoma may limit injury of the brain, but the decision about whether and when to undertake surgical evacuation of ICH remains controversial.<sup>5</sup> For patients who have lobar ICH >30 mL and within 1 cm of the surface, removal of supratentorial ICH by standard craniotomy might be considered.<sup>2</sup> However, the effectiveness of minimally invasive ICH evacuation using an endoscopic approach is uncertain and is considered investigational.<sup>2</sup> With the advancement of the neuroendoscopic system and instruments, recent reports have demonstrated a high rate of ICH evacuation of 84–99%.<sup>6–10</sup> In addition, several series have reported a lower rate of rebleeding, morbidity and mortality in

endoscopic hematoma evacuation surgery than in traditional craniotomy.<sup>6,11</sup> The main reasons were less adjacent tissue injury, less blood loss, and less operation time. True minimally invasive surgery includes not only a minimal wound size but also minimal brain tissue trauma during the surgery.

In endoscopic surgery, setting up a good working channel is an important step. Many working channels such as the transparent sheath or other handmade sheaths have been developed and reported in the literature.<sup>7,9,10,12,13</sup> However, how to construct the tract in an easy and safe manner is important as well. We used a handmade rubber balloon catheter to create a tract, and then a transparent sheath or retractor was inserted along this tract. The use of the rubber balloon catheter for approaching deep intracerebral space-occupying lesions was first reported by Hirsch et al<sup>14</sup> in 1990. This technique has been proven to minimize damage to the nervous tissue along the trajectory.<sup>15</sup> In our cases, minimal tissue loss along the

Table 1  
General data of the 45 patients with spontaneous supratentorial ICH.

Parameter	Endoscopy group (n = 21)		Craniotomy group (n = 24)	
	Value	Range or %	Value	Range or %
Age (y/o)	57.3	36–85	56.9	18–80
Sex (F: M)	6:15		5:19	
Locations				
Putamen	16	76	17	71
Lobar (Subcortical area)	5	24	7	29
ICH volume (mL)	61.2	30–140	47.1	32–110
Initial GCS (median)	8	4–14	7	4–14
Surgery within 6 h	19	90	20	83
Medical morbidity				
Hypertension	20	95	21	88
DM	12	57	14	58
Renal insufficiency	1	5	0	0
Liver cirrhosis	1	5	0	0
Coagulopathy	2	9	0	0
Entry point				
Kocher's	19	90	—	
Keen's	1	5	—	
Frazier's	1	5	—	

DM = diabetes mellitus; F = female; GCS = Glasgow Coma Scale; ICH = intracerebral hematoma; IVH = intraventricular hemorrhage; M = male.

trajectory, as seen in postoperative CT, may be evidence of limited brain tissue damage (Fig. 1). Although ICP elevation was seen during balloon inflation, the degree of elevation was limited because of the contralateral extraventricular drainage of the cerebrospinal fluid. In addition, the inflation time was limited to remain within the threshold of cerebral ischemia time (usually within 4 minutes). Such handmade rubber balloon catheters are economical and available in most neurosurgical institutes.

Hemostasis is another challenge with endoscopic surgery. Unfamiliarity with the free-hand technique and the limitation of instruments make hemostasis more difficult than with

Table 2  
Operative results of 45 patients with spontaneous supratentorial ICH.

Parameter	Endoscopy group (n = 21)		Craniotomy group (n = 24)		
	Values	Range or %	Values	Range or %	
Median operation time (min)	120	90–190	230	120–460	0.009
Median blood loss (mL)	160	50–300	530	100–2000	<0.001
Median evacuation rate (%)	90	60–99	85	52–100	0.703
Median ICU stay (d)	6	2–18	11	7–26	0.017
Permanent VP shunt	5	24	7	30	0.746
Rebleeding (n)	2 <sup>a</sup>	9.5	1	4	0.591
Mortality (n)	2 <sup>b</sup>	9.5	1	4	0.591
Median GCS (1 wk later)	11	8–15	11	4–15	0.349
Median GOS (6 mo later)	3	1–4	3	1–4	0.901
Median GOS (1 y later)	3	1–4	3	1–4	0.783

GCS = Glasgow Coma Scale; GOS = Glasgow Outcome Scale; ICU = intensive care unit; VP = ventriculoperitoneal.

<sup>a</sup> Rebleeding in original location in one patient (Day 3), and in a remote location (midbrain intracerebral hematoma) in another (Day 7).

<sup>b</sup> Cause of death: rebleeding in one patient and pneumonia in another.

traditional microsurgery. Although a few multifunctional instruments have already been developed to overcome this limitation, a further problem is that the equipment is expensive. In our practice, we use suction only to evacuate the hematoma, and bipolar forceps to coagulate small capillary oozing. We believe fast decompression is more important than total removal of the hematoma, so we use the suction power to select which part of the hematoma can be removed. A thin hematoma over the surrounding brain tissue should be left intact. We also used hemostatic agents such as Floseal instead of coagulation if there is merely minor oozing. In our series, the rebleeding rate was 9.5% (2 of 21 patients), which was higher than in other series. However, the rebleeding in these two patients did not happen immediately after surgery, but 3 days later. Poor control of hypertension was the main cause. Therefore, strict blood pressure control postoperatively plays an important role in preventing rebleeding as well as hemostasis.

In our series, improvement in the GCS 1 week after surgery was noted in most of the patients. Furthermore, deterioration of the GCS after surgery was found in two of 21 patients because of rebleeding. As for functional recovery, the median GOS evaluated 6 months and 1 year postoperatively was 3. Our result was similar to that of other series which showed good short-term surgical outcome for endoscopic surgery, but no benefit for long-term functional recovery. Nevertheless, a shorter ICU stay means that the endoscopic approach for supratentorial ICH is more cost-effective, both to the family and the national insurance program. From the viewpoint of a neurosurgeon, less surgical trauma and stress do assist ICH patients in an earlier beginning of their course of rehabilitation, and to avoid further deadly complications of ICH. Although there was no large randomized clinical study to compare with traditional craniotomy, there was a trend toward a shorter ICU stay with endoscopic surgery because of the lower post-surgery comorbidity and immediate release of ICP after surgery.<sup>6</sup>

However, some debate regarding this endoscopic procedure still exists: which patients are suitable for endoscopic approach and when is the appropriate surgical timing? Many reports have shown that the surgical decompression for

Table 3  
Analysis of 21 ICH patients who underwent endoscopic hematoma evacuation, in terms of the different locations.

	Putaminal ICH (n = 16)	Subcortical ICH (n = 5)
No. of patients	16	5
Median hematoma evacuation rate (%)	92	86
Re-bleeding rate (%)	13	0
Mortality		
No. of patients (%)	2 (13)	0
Median GCS score		
Pre-operation	8	11
1 wk after operation	10	13
Median GOS score (6 mo post-operation)	3	3

GCS = Glasgow Coma Scale; GOS = Glasgow Outcome Scale; ICH = intracerebral hematoma.

spontaneous ICH is only suitable for a small percentage of the patient population, that is, where GCS is  $\geq 8$ , and moderate ICH volume.<sup>2</sup> However, evidence of tangible improvement of surgical outcomes is lacking when the minimally invasive method for endoscopy is used. By contrast, American Heart Association/American Stroke Association guidelines for the management of spontaneous ICH indicate that no clear evidence demonstrates that early removal of supratentorial ICH improves functional outcome or the mortality rate.<sup>5</sup> Early craniotomy may be harmful due to the increased risk of recurrent bleeding,<sup>16</sup> although Kuo et al<sup>17</sup> thought that the earlier (within 12 hours) endoscopic evacuation was performed, the higher the evacuation rate that could be achieved. Therefore, further randomized controlled studies for endoscopic ICH evacuation are necessary to elucidate better these important issues.

The limitations of this study were its retrospective nature and limited patient numbers. Although we attempted to send ICH patients who needed surgical decompression to surgery as early as possible, we were not precisely able to recognize the onset time of hemorrhage. Some hemorrhagic episodes occurred at night, and some caregivers were too anxious to record the onset time of symptoms. In addition, the patients included in our study were highly selected and represented only 23% ( $n = 45/198$ ) of all ICH patients that we encountered in a 14-month period. We performed an endoscopic approach on 47% ( $n = 21/45$ ) of those patients who were willing to receive surgical decompression. Some patients with poor prognostic factors of ICH were excluded from this study. As a result, the outcome of our study may seem better than in the general surgical population. Last but not least, the advantage of surgical hematoma evacuation is controversial in the patients who had GCS  $< 8$  prior to surgery, although some of our patients showed acceptable recovery. However, further randomized controlled studies are necessary to prove the safety and effectiveness of the endoscopic technique.

In conclusion, endoscopic hematoma evacuation for spontaneous supratentorial hemorrhage is becoming a standard surgical procedure, and promising clinical results can be expected. The authors have found that using the endoscope can create an improved view, reduce bleeding, and enhance time efficiency. Therefore, being familiar with the endoscope and related instrumentation is the best way to create a better result and fewer complications.

## References

- Dennis MS. Outcome after brain haemorrhage. *Cerebrovasc Dis* 2003;16(Suppl):9–13.
- Mendelow AD, Gregson BA, Fernandes HM, Murray GD, Teasdale GM, Hope DT, et al. Early surgery versus initial conservative treatment in patients with spontaneous supratentorial intracerebral haematomas in the International Surgical Trial in Intracerebral Haemorrhage (STICH): a randomised trial. *Lancet* 2005;365:387–97.
- Snell JW, Sheehan J, Stroila M, Steiner L. Assessment of imaging studies used with radiosurgery: a volumetric algorithm and an estimation of its error. Technical note. *J Neurosurg* 2006;104:157–62.
- Xi G, Wagner KR, Keep RF, Hua Y, de Courten-Myers GM, Broderick JP, et al. Role of blood clot formation on early edema development after experimental intracerebral hemorrhage. *Stroke* 1998;29:2580–6.
- Morgenstern LB, Hemphill 3rd JC, Anderson C, Becker K, Broderick JP, Connolly Jr ES, et al. Guidelines for the management of spontaneous intracerebral hemorrhage: a guideline for healthcare professionals from the American Heart Association/American Stroke Association. *Stroke* 2010;41:2108–29.
- Cho DY, Chen CC, Chang CS, Lee WY, Tso M. Endoscopic surgery for spontaneous basal ganglia hemorrhage: comparing endoscopic surgery, stereotactic aspiration, and craniotomy in noncomatose patients. *Surg Neurol* 2006;65:547–55.
- Hsieh PC, Cho DY, Lee WY, Chen JT. Endoscopic evacuation of putaminal hemorrhage: how to improve the efficiency of hematoma evacuation. *Surg Neurol* 2005;64:147–53.
- Nagasaka T, Tsugeno M, Ikeda H, Okamoto T, Inao S, Wakabayashi T. A novel monoshaft bipolar cautery for use in endoscopic intracranial surgery. A short technical note. *Clin Neurol Neurosurg* 2011;113:607–11.
- Nagasaka T, Tsugeno M, Ikeda H, Okamoto T, Takagawa Y, Inao S, et al. Balanced irrigation-suction technique with a multifunctional suction cannula and its application for intraoperative hemorrhage in endoscopic evacuation of intracerebral hematomas: technical note. *Neurosurgery* 2009;65:E826–7.
- Nishihara T, Teraoka A, Morita A, Ueki K, Takai K, Kirino T. A transparent sheath for endoscopic surgery and its application in surgical evacuation of spontaneous intracerebral hematomas. Technical note. *J Neurosurgery* 2000;92:1053–5.
- Nagasaka T, Tsugeno M, Ikeda H, Okamoto T, Inao S, Wakabayashi T. Early recovery and better evacuation rate in neuroendoscopic surgery for spontaneous intracerebral hemorrhage using a multifunctional cannula: preliminary study in comparison with craniotomy. *J Stroke Cerebrovasc Dis* 2010;20:208–13.
- Chen CC, Chung HC, Liu CL, Lee HC, Cho DY. A newly developed endoscopic sheath for the removal of large putaminal hematomas. *J Clin Neurosci* 2009;16:1338–41.
- Chen CC, Lin HL, Cho DY. Endoscopic surgery for thalamic hemorrhage: a technical note. *Surg Neurol* 2007;68:438–42.
- Hirsch JF, Rose CS, Pierre-Kahn A, Renier D, Hoppe-Hirsch E. Neurosurgery with craniotomy and CT stereotactic guidance in the treatment of intracerebral space-occupying lesions. *Child's Nerv Syst* 1990;6:323–6.
- Shahbadian S, Keller JT, Gould 3rd HJ, Dunsker SB, Mayfield FH. A new technique for making cortical incisions with minimal damage to cerebral tissue. *Surg Neurol* 1983;20:310–2.
- Morgenstern LB, Demchuk AM, Kim DH, Frankowski RF, Grotta JC. Rebleeding leads to poor outcome in ultra-early craniotomy for intracerebral hemorrhage. *Neurology* 2001;56:1294–9.
- Kuo LT, Chen CM, Li CH, Tsai JC, Chiu HC, Liu LC, et al. Early endoscope-assisted hematoma evacuation in patients with supratentorial intracerebral hemorrhage: case selection, surgical technique, and long-term results. *Neurosurg Focus* 2011;30:E9.