



Does ischemia reperfusion affect fecundability in a rat model?

Pinar Calis*, Nergis Erturk, Gurkan Bozdog

Department of Obstetrics and Gynecology, Hacettepe University School of Medicine, Ankara, Turkey

Abstract

Background: Adnexal torsion constitutes 2.7% of all gynecological emergencies. Because normal follicular growth has been demonstrated after examination of surgical specimens retrieved from oophorectomies, organ-sparing strategy has gained more popularity irrespective of the appearance of the ovary. However, the functionality of the remaining follicles has not been known. The aim of the study was to evaluate the effect of ischemia-reperfusion on fecundability in a rat model with adnexal torsion.

Methods: A total of 30 female adult Wistar albino rats were assessed. In the first laparotomy, right ovaries were twisted for 8 (Group I, n = 10) or 24 (Group II, n = 10) hours. Second laparotomy was performed to untwist the torsion side and oophorectomy to the other side. In the control group (Group III, n = 10), left ovaries were removed and right ovaries were kept without any intervention. After 30 days from the last operation, female rats were mated for 10 days and euthanized 4 days later. Fecundability was calculated using beta-human chorionic gonadotropin (hCG) levels for detection of pregnancy rates.

Results: The mean beta-hCG values in control, 8-hour, and 24-hour groups between pregnant rats were 19.8 ± 26.02 , 11.7 ± 0.17 , and 22.97 ± 11.87 mIU/mL, respectively. Whereas two out of 10 rats (20%) conceived in the 8-hour group, three out of 10 rats (30%) got pregnant in the 24-hour group. In total, whereas five out of the 20 rats got pregnant in the experimental groups, in the control group, seven out of 10 subjects conceived (25% vs 70%, $p = 0.018$).

Conclusion: Although there was a statistical difference between experimental and control groups, statistical significance was not reached among 8-hour and 24-hour torsion subgroups. In this context, patients with torsion but treated with detorsion should be further investigated for their fecundability potency and be informed accordingly.

Keywords: Fecundability; Ischemia; Reperfusion injury

1. INTRODUCTION

Adnexal torsion entails twisting vascular supply to the ovary and constitutes 2.7% of all gynecological emergencies.¹⁻³ The strategy for treatment depends on several conditions such as intra-operative macroscopic appearance of the twisted ovary, desire for further childbearing, and presence of accompanying ovarian mass, if any.^{4,5} In this context, once the affected side is dark and black bluish in color, oophorectomy is generally preferred due to lack of any expectation for viability and functionality.

The management of adnexal torsion has been challenged in recent years. Because normal follicular growth has been demonstrated after examination of surgical specimens retrieved from oophorectomies,⁶ organ-sparing strategy has gained more popularity irrespective of the appearance of the ovary.⁷⁻⁹ Nevertheless, there are a few data about the influence of free

radicals on ovarian reserve originated from reperfusion injury during untwisting the gonad.¹⁰ In addition to the conventional approach, oophoropexy is also suggested in high-risk population. On this issue, recently, comparable number of follicles after 16 hours of torsion in a rat model was documented but with a less viability on the affected side established by immunohistochemical staining with Proliferating cell nuclear antigen.¹¹ However, resulting fecundability rates in these cases have never been investigated either in human subjects or in an experimental animal model.

The primary aim of this study was to evaluate whether fecundability is altered after torsion and detorsion of the ovary due to ischemia-reperfusion injury when compared with that of controls in an animal model.

2. METHODS

A total of 30 female, fertile adult Wistar albino rats, 15 weeks old, weighing 200 to 220 g, were used in this study. All animals were obtained from the Hacettepe University, Animal Research Center; kept in a standardized temperature and humidity environment and 12-hour day/night cycle; and were fed ad libitum. All experimental procedures were performed following the approval of institutional ethical committee on animal research (Approval No: 2015 06/07).

Surgery was performed under general anesthesia with intraperitoneal administration of ketamine hydrochloride (50 mg/kg Ketalar; Eczacibasi, Istanbul, Turkey) and xylazine hydrochloride (10 mg/kg Rompun; Bayer Türk Ilac Ltd., Istanbul, Turkey).

*Address correspondence: Dr. Pinar Calis, Department of Obstetrics and Gynecology, Hacettepe University School of Medicine, Sıhhiye, Ankara 06100, Turkey. E-mail address: ptokdemir86@gmail.com (P. Calis).

Conflicts of interest: The authors declare that they have no conflicts of interest related to the subject matter or materials discussed in this article.

Journal of Chinese Medical Association. (2019) 82: 515-518.

Received August 10, 2018; accepted September 29, 2018.

doi: 10.1097/JCMA.0000000000000052.

Copyright © 2019, the Chinese Medical Association. This is an open access article under the CC BY-NC-ND license (<http://creativecommons.org/licenses/by-nc-nd/4.0/>).

After cleaning the operation site with antiseptic solution (Baticon, Drogosan, Turkey), laparotomies were performed via a 25-mm midline-vertical incision.

In the experimental groups (Groups I and II), right ovaries were twisted at 720° in counter clockwise with microsurgical forceps and fixed to the peritoneum using a 4-0 vicryl suture (Johnson & Johnson, Neenah, WI, USA) for a duration of 8 (Group I, n = 10) or 24 (Group II, n = 10) hours. A second laparotomy was performed to untwist the torsion sides and relieve the vascular compromise after either 8 or 24 hours depending on the assignment of the experimental group (Fig. 1). In all animals, the contralateral unaffected ovaries were totally removed to exclude the possibility of ovulation from the healthy side in all groups. In the control group (Group III, n = 10), first laparotomy was performed without doing any intervention to adnexa and subsequently second laparotomy to perform oophorectomy to the left side.

After 30 days from the second operation, female rats were mated for 10 days and euthanized 4 days later. At the end of the study duration, all animals were euthanized with high-dose anesthetic administration after obtaining intracardiac blood for detection of serum beta-hCG levels. All blood samples were centrifuged at 3000g for 15 minutes, and serum samples were kept at -20°C until biochemical assessment. All serum specimens were analyzed with the Enzyme-linked immunosorbent assay (ELISA) method (rat hyperglycosylated free-beta chorionic gonadotropin; MyBioSource, San Diego, CA, USA) to quantify beta-hCG concentration. The intra-assay and interassay precision rates were ≤8% and ≤12, respectively. Detection range was 7.8 to 500 mIU/mL for the exposed assay. Fecundability was defined by the percentage of animals conceived according to beta-hCG concentration exceeding 1 mIU/L, as reported previously.¹²

2.1. Statistical analysis

Descriptive statistical data were expressed as mean ± standard deviation, median, and minimum and maximum values. The chi-square and Fisher's exact tests were used to analyze nominal variables in the form of frequency tables using Statistical Package for the Social Sciences (ver. 21.0; SPSS Inc., Chicago, IL). If expected values were <5 in a cell, we preferred to use Fisher's exact test instead of chi-square test. *p* value of <0.05 was considered as statistically significant.

3. RESULTS

For the Groups I, II, and III, the mean free beta-hCG levels were 19.8 ± 26.02, 11.7 ± 0.17, and 22.97 ± 11.87 mIU/mL, respectively. The mean duration of the first laparotomy (torsion procedure) was 8.2 ± 3.4 minutes. The mean duration for the second laparotomy (detorsion and oophorectomy procedures) was 11.3 ± 4.6 minutes. The pregnancy rates of the groups are demonstrated in Figure 2. The average pregnancy rates were found to

be 20.0 % and 30.0 % for the 8 and 24 hours of torsion group, respectively, whereas the average pregnancy rate was found to be highest in the control group (70.0 %). The pregnancy rates between the two groups that experienced ovarian torsion were found to be comparable (*p* > 0.005). The difference between pregnancy rates was not statistically significant when 8-hour and 24-hour groups were compared with control individually (*p* = 0.07 and *p* = 0.18, respectively). When the total pregnancy rates of the experimental groups (Groups I and II) were compared with those of the control group (Group III), the difference was found to be significantly different (*p* = 0.018).

4. DISCUSSION

In the current study, it was aimed to evaluate whether fecundability is affected after torsion and detorsion of the ovary due to ischemia-reperfusion injury. The resulting findings suggest that although there was follicular growth, for follicle functionality, ovarian torsion might impair fecundability as depicted in a rat model, when treated with detorsion.

To best of our knowledge, there is no study evaluating the fecundability when ovarian torsion was treated with detorsion in a rat model. The previous study of our group had revealed that ovarian reserve reflected by primordial and primary follicle count did not change in a rat model, when torsion side and contralateral ovaries were compared,¹¹ but there were subtle histological changes under microscopic examination and diminished viability of the observed follicles, particularly after duration of 16 hours of torsion. These former findings had induced us to design the current experimental model to detect the viability of remained follicles as will be reflected by fecundability after detorsion of the twisted side. If the study groups were compared with the control group, there was a lower fecundability as defined by the percentage of animals conceived in study groups. One may expect that fecundability should be lower in the 24-hour group when compared with that of the 8-hour group. In this context, the lack of any statistical difference might be related to two points. First, small sample size in each arm might limit the ability to find statistical difference. However, to observe a statistical difference among groups that have fecundability rates of 20% and 30%, we need a total of 137 subjects in these two groups, when the power is set to 80%. Second, because we do not know the minimum duration of torsion requiring any impairment on fecundability, it might be speculated that 8 hours might be enough to make any potential damage on oocyte compatibility and hence implantation.

The interpolation of experience from animal studies to human needs caution. In this respect, in a previous study conducted with humans,¹³ ovarian reserve had been also evaluated by counting antral follicles and estimating the ovarian volume with ultrasonography among 18 women with a previous history of adnexal torsion. Notably, both mean antral follicle count and

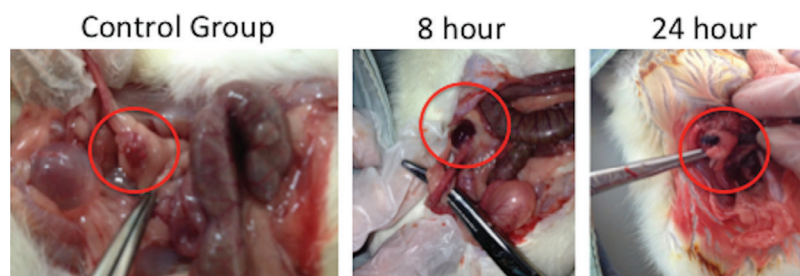


Fig. 1 Macroscopic appearance of control group and twisted ovaries (8 and 24 h) in the second laparotomy. Black-bluish and dark appearance was present in both experimental groups

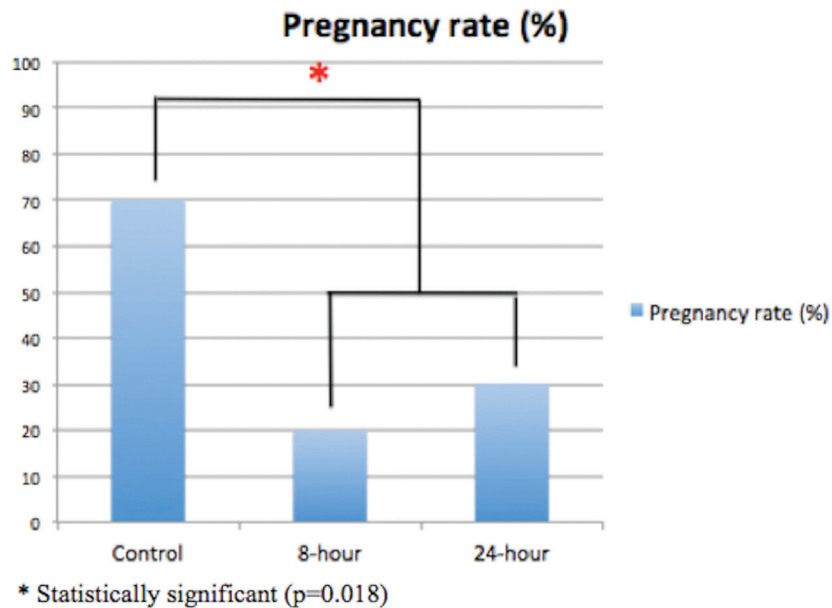


Fig. 2 Pregnancy rates (%) for each group. There was statistical significance between control and study groups (8 and 24 h)

ovarian volume were comparable among the operated and contralateral ovaries in these patients when they were treated with untwisting the ovary solely. However, although ovarian reserve markers are highly predictive of ovarian response in assisted reproduction treatments, one should keep in mind that none of them add significant information to the limited capacity of female age to predict ongoing pregnancy chance after in vitro fertilization treatment.¹⁴ From this standpoint, beyond status of ovarian reserve, ovarian reserve does not represent the total fecundability potential and there is lack of data whether patients complicated with ovarian torsion experience altered fecundability after saving their ovaries. This study is a pioneer one evaluating the fecundability potential when ovarian torsion was treated with detorsion in a rat model.

The observed significant decrease in fecundability might be related not only to ischemia itself but also to reperfusion injury. Whereas ischemia increases blood levels of lactic acid, hypoxanthine, and lipid peroxidation products,^{15,16} detorsion and reperfusion cause excessive release of reactive oxygen species and free radicals that are related to DNA and cellular damage,^{17,18} which in turn cause damage to the functionality of the existing follicles. These mechanisms might alter granulosa cell functions or directly affect oocyte. Notably, there might be different durations of thresholds for primordial follicle count, viability of follicles, and fecundability before a significant alteration could be apparent. As reported in a previous study,¹¹ although there was a similar primordial and primary follicle count between torsioned and contralateral ovaries, the viability of the remaining follicles as reflected by immunohistochemical staining (PCNA) was impaired in the 16-hour group but not in 2- or 4-hour group. Therefore, one may claim that fecundability might be impaired after 8 hours of torsion, whereas histological findings might be determined after a longer period of ischemia.

One of the major limitations of the study might be setting the trial on an animal model with their inherent disadvantages.¹¹ Although the preliminary results obtained from this animal study, we believe would be basis of upcoming clinical trials. Moreover, future studies should prospectively follow women complicated with ovarian torsion and evaluate their long-term outcome with regard to their fecundability. Unfortunately, it

would not be feasible to evaluate the relationship between duration of torsion and fecundability, because the early symptoms might be insignificant to detect the onset of ischemia precisely.¹⁹ In this regard, the findings on animal model might be useful to speculate and discuss with patients about their fecundability. Finally, because the contralateral ovary has been removed in the current study to observe the fecundability of the operated side, the contribution of the contralateral healthy ovary on reproduction capacity in real life cannot be excluded. However, there are a few groups of patients who had experienced ovarian torsion in both sides during different time periods of their lifespan,²⁰ and consultation might be given for their potential fertility problems under the view of these findings.

As a conclusion, patients with torsion but treated with detorsion should be further investigated for their fecundability potency and be informed accordingly. To confirm these findings, further prospective studies on humans with long-term follow-up are required to observe fecundability capacity of women who had experienced ovarian torsion.

ACKNOWLEDGMENTS

This study was funded by Hacettepe University Research Committee (Project No: TDS-2015-5843; no involvement in study design, collection, analysis, and writing the report.)

REFERENCES

- Childress KJ, Dietrich JE. Pediatric ovarian torsion. *Surg Clin North Am* 2017;97:209-21.
- Hibbard LT. Adnexal torsion. *Am J Obstet Gynecol* 1985;152:456-61.
- McWilliams GD, Hill MJ, Dietrich CS 3rd. Gynecologic emergencies. *Surg Clin North Am* 2008;88:265-83.
- Harkins G. Ovarian torsion treated with untwisting: second look 36 hours after untwisting. *J Minim Invasive Gynecol* 2007;14:270.
- Aziz D, Davis V, Allen L, Langer JC. Ovarian torsion in children: is oophorectomy necessary? *J Pediatr Surg* 2004;39:750-3.
- Santos XM, Cass DL, Dietrich JE. Outcome following detorsion of torsed adnexa in children. *J Pediatr Adolesc Gynecol* 2015;28:136-8.
- Galinier P, Carfagna L, Delsol M, Ballouhey Q, Lemasson F, Le Mandat A, et al. Ovarian torsion. Management and ovarian prognosis: a report of 45 cases. *J Pediatr Surg* 2009;44:1759-65.

8. Oelsner G, Cohen SB, Soriano D, Admon D, Mashiach S, Carp H. Minimal surgery for the twisted ischaemic adnexa can preserve ovarian function. *Hum Reprod* 2003;18:2599–602.
9. Oelsner G, Bider D, Goldenberg M, Admon D, Mashiach S. Long-term follow-up of the twisted ischemic adnexa managed by detorsion. *Fertil Steril* 1993;60:976–9.
10. Comeau IM, Hubner N, Kives SL, Allen LM. Rates and technique for oophoropexy in pediatric ovarian torsion: a single institution case series. *J Pediatr Adolesc Gynecol* 2017;30:418–21.
11. Calis P, Bozdogan G, Karakoc Sokmensuer L, Kender N. Does ischemia-reperfusion injury affect ovarian reserve and follicle viability in a rat model with adnexal torsion? *Eur J Obstet Gynecol Reprod Biol* 2015;185:126–30.
12. Alexander MH, Lazan KS, Rasmussen KM. Effect of chronic protein-energy malnutrition on fecundability, fecundity and fertility in rats. *J Nutr* 1988;118:883–7.
13. Bozdogan G, Demir B, Calis PT, Zengin D, Dilbaz B. The impact of adnexal torsion on antral follicle count when compared with contralateral ovary. *J Minim Invasive Gynecol* 2014;21:632–5.
14. Broer SL, van Disseldorp J, Broeze KA, Dolleman M, Opmeer BC, Bossuyt P, et al. Added value of ovarian reserve testing on patient characteristics in the prediction of ovarian response and ongoing pregnancy: an individual patient data approach. *Hum Reprod Update* 2013;19:26–36.
15. Bozkurt S, Arikian DC, Kurutas EB, Sayar H, Okumus M, Coskun A, et al. Selenium has a protective effect on ischemia/reperfusion injury in a rat ovary model: biochemical and histopathologic evaluation. *J Pediatr Surg* 2012;47:1735–41.
16. Taskin O, Birincioglu M, Aydin A, Buhur A, Burak F, Yilmaz I, et al. The effects of twisted ischaemic adnexa managed by detorsion on ovarian viability and histology: an ischaemia-reperfusion rodent model. *Hum Reprod* 1998;13:2823–7.
17. Akgür FM, Kiliç K, Aktuğ T. Reperfusion injury after detorsion of unilateral testicular torsion. *Urol Res* 1993;21:395–9.
18. Li C, Jackson RM. Reactive species mechanisms of cellular hypoxia-reoxygenation injury. *Am J Physiol Cell Physiol* 2002;282:C227–41.
19. Schuh AM, Klein EJ, Allred RJ, Christensen A, Brown J. Pediatric adnexal torsion: not just a postmenarchal problem. *J Emerg Med* 2018;54:131–2.
20. Kurtoglu E, Kokcu A, Danaci M. Asynchronous bilateral ovarian torsion. A case report and mini review. *J Pediatr Adolesc Gynecol* 2014;27:122–4.